

EVANS SYNDROME : A CASE REPORT

Fauzio N. Khaira^{1*}, Mohamad Syaikhul I.², Arief A. Rahman³, Selfie C. Rijal⁴¹General Practitioner of Balaraja Hospital²General Practitioner of Jailolo Hospital³General Practitioner of Permata Cibubur Hospital⁴Internist of Balaraja Hospital***Corresponding Author:-**fauzio_khaira@yahoo.com**Abstract**

Evans Syndrome (ES) is a rare autoimmune disorder characterized by the presence of autoimmune hemolytic anemia (AIHA) and immune thrombocytopenia purpura (ITP). The average patients were diagnosed at the age of 52 years with a female-to-male ratio of 3:2. A 43-year-old woman, with complaint of spontaneous bleeding of the gum ten hour prior to hospital. Pressure bandages have been applied but bleeding still occurs. There was no previous history of bleeding disorder or family history of bleeding disorder. There are ulcers that occur spontaneously on the left thigh and lower leg. The patient has a history of 5 miscarriages. The patient comes with stable vital signs. Physical examination shows anemic conjunctiva, active bleeding in the left gum, ulcers on the back of the left thigh and on the left lower leg. Laboratory findings showed hemoglobin 6.0, leukocytes 4770, platelets 79.000, reticulocytes 1.8%. BUN and electrolyte were normal. Peripheral blood morphology shows normochromic normocytic anemia with increased erythropoietic response and thrombocytopenia suggests a chronic process with bleeding. Immunoserological examination shows direct antiglobulin test (DAT) +1, immature platelet fraction (IPF) 7.9%. HIV test, anti-HCV and HBSag were non-reactive. The therapy given includes high-dose steroids, antibiotic, blood transfusions and symptomatic therapy. The patient was discharged after 6 days with clinical recovery. Laboratory findings of normochromic normocytic anemia with DAT +1 results suggest AIHA. Thrombocytopenia in a patient with elevated IPF suggest ITP. The presence of these two findings leads to the diagnosis of ES. A spontaneous ulcer can be a sign of blood vessel thrombosis that can occur in ES. History of recurrent miscarriage leads to secondary ES with antiphospholipid syndrome (APS). Futher blood test is needed to determine the cause of bleeding and antiphospholipid syndrome.

Keywords: *Evans Syndrome, Spontaneous Bleeding, Antiphospholipid Syndrome*

INTRODUCTION

Evans Syndrome (ES) is a rare autoimmune disorder characterized by the presence of autoimmune hemolytic anemia (AIHA) and immune thrombocytopenia purpura (ITP). The symptoms of Evans syndrome can vary greatly from one individual to the next, ranging from self-controlled to relapsing-remitting in some situations. There are a lot of cases that only show a temporary response to treatment, but relapses are extremely prevalent.¹ The average patients were diagnosed at the age of 52 years with a female-to-male ratio of 3:2. A recent statewide research in Denmark that reported on 242 patients who have been handled over the last 40 years has contributed to the refinement of our understanding of the epidemiology of ES in adults (1977–2017).^{2,3}

An yearly incidence rate of 1.8 per million person-years and an annual prevalence rate of 21.3 per million people were cited as supporting evidence for the rarity of the illness. In terms of isolated AIC, ES accounts for between 0.3 and 7% of AIHA and between 2 and 2.7% of ITP. In adults, autoimmune cytopenia (AIC) may occur simultaneously in 30–57% of cases, but autoimmune hemolytic anemia (AIHA) can come first in 27–44% of cases. The average amount of time that passes between each AIC is three years; however, this number may vary greatly.^{2,3}

Recent study has led to the formulation of a hypothesis that proposes classifying the illness as either primary (idiopathic) or secondary (related with an underlying disorder).^{2,3} Secondary Evans syndrome has been linked to diseases like systemic lupus erythematosus (SLE), common variable immunodeficiency (CVID), and autoimmune lymphoproliferative syndrome (ALPS) in Non-Hodgkin lymphoma (NHL) in patients older than 50 years, chronic lymphocytic leukemia (CLL), viral infections, and following allogeneic hematopoietic cell.¹

This disorder is an uncommon disease, and as such, there is no set standard for its therapy. In addition, the diagnosis that is established for people with ES has to rule out a large number of other diseases that might be a possibility. A patient diagnosed with ES who is 42 years old is the focus of this case report.

CASE ILUSTRATION

A 43-year-old female admitted to hospital with complaints of bleeding in her mouth area since dawn. The patient's family admitted that a stone fell in the yard of the house a week ago, injuring the patient's chin. The wound on the chin was brought to the clinic and treated with 2 hectings. She was back to normal activity after wound healed and she could eat or drink as usual, but today at around 5.00 a.m., she admitted that his mouth was bleeding. Her family claimed that she developed sores on her nails two months before fasting, but that they healed after she visited the clinic's doctor.

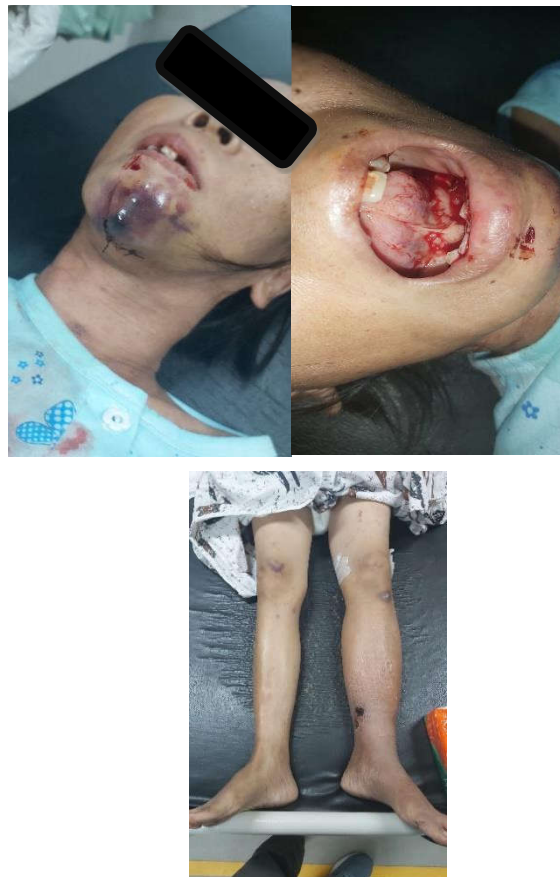

Figure 1. The patient's clinical photograph

This year, shortly after Eid Al-Fitr, there was a scab behind the left thigh and front left lower leg, accompanied by a large swelling. Scabs frequently emerge from a clear, pungent liquid. As time passed, her feet became increasingly swollen, prompting her family to take her to Cikupa Health Center. Cikupa Health Center advised the patient to be taken to the hospital. She went to the Internal Medicine Polyclinic at Balaraja Hospital, complaining of reduced swelling and

scheduling a control on July 20, 2022. The patient has a history of miscarriage at 4-5 months of pregnancy 5 times. There is no fever, cough, runny nose, sore throat, anosmia, or ageusia.

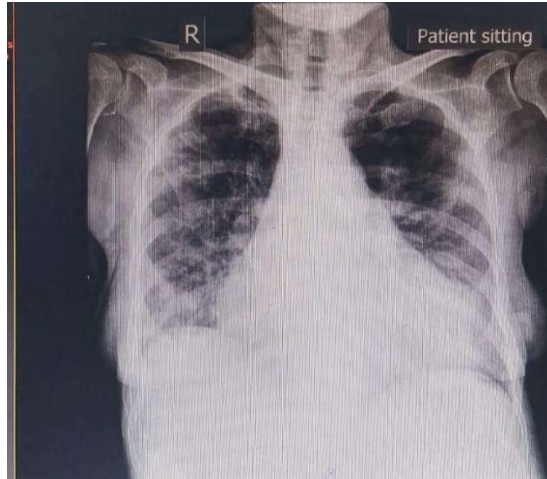


Figure 2. Chest x-ray

Examination of vital signs revealed that the patient was compositing mentis, BP = 148/95 mmHg, HR = 106 bpm, RR = 22 rpm, SpO2 98% room water, and temperature = 36.8 C. Anemic conjunctiva, active bleeding in the left gum, ulcers on the back of the left thigh, and ulcers on the left lower leg are all found over the course of the physical examination.

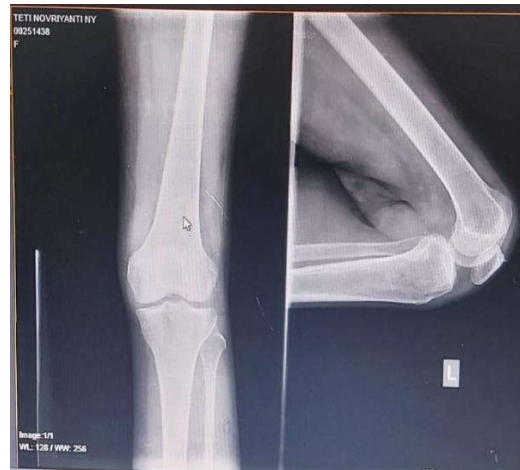

Figure 3. Knee x-ray

Laboratory examination found Hb = 6.0 g/dL; Htc = 19%; leukocytes = 4,770 /mm³; platelets = 79,000/mm³; SGOT = 19 U/L; SGPT = 38 U/L; blood urea = 61 mg/dL; creatinine = 1.1 mg/dL; sodium = 134 mmol/L; potassium = 4.2 mmol/L; chloride = 106 mmol/L. Negative COVID-19 screening results. The results of the chest x-ray examination showed cardiomegaly. She was diagnosed with anemia ec melena + suspension AIHA dd Evan syndrome + suspension antiphospholipid syndrome + AKI stg risk + posterior femoral a/r ulcer + left a/r pedis cellulitis + mental a/r hematoma. Therapy given to the patient, among others, NaCl 0.9% 500 cc/8 hours; omeprazole injection 40 mg/12 hours; tranexamic acid injection 500 mg/8 hours; Ketorolac injection 30 mg/8 hours. She received four unit PRC transfusions, metronidazole 500 mg/8 hours, ceftriaxone 1 gr/12 hours; dexamethasone 3 mg/8 hours and vitamin K during hospitalization. The result of post-transfusion hemoglobin examination after 6th treatment day was 10. gr/dL. Immunoserological examination shows direct antiglobulin test (DAT) +1, immature platelet fraction (IPF) 7.9%. HIV test, anti-HCV and HBsag were non-reactive. The result of the consultation with the orthopedic doctor was a knee x-ray examination. Orthopedic specialist's recommendation for GV moist-dry wound dressing every 3 days.

DISCUSSION

A 43-year-old female had been complaining for ten hours previous to her visit to the hospital of gum bleeding that had occurred spontaneously. Despite the use of pressure bandages, bleeding continues despite the situation. Ulcers have formed all by themselves on the lower leg and left thigh of the affected individual. She's diagnosed with Evans' syndrome. Evans' syndrome (ES) defined as the concurrent or sequential occurrence of ITP and AIHA. AIHA known as ES-anaemia is caused by warm antibodies, which are almost often of the IgG isotype but sometimes the IgA isotype.⁴

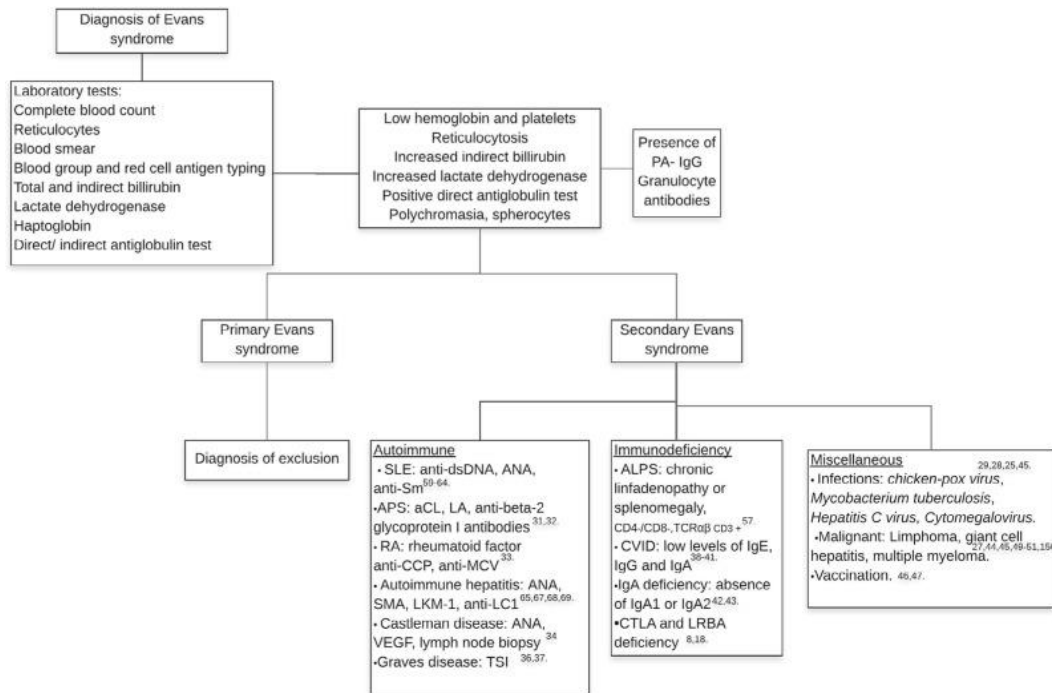


Figure 4. Diagnostic approach for Evans syndrome⁵

The signs and symptoms of Evans syndrome may vary significantly depending on the kinds of blood cell lines that are damaged by the condition. They may exhibit symptoms such as weariness, pallor, dizziness, shortness of breath, and a restriction in their ability to engage in physically taxing activities when AIHA is present. A physical examination will often reveal jaundice and a pale complexion. The size of the spleen may be increased.² AIHA is suspected in case of anaemia (haemoglobin <11 g/dL for female and <12 g/dL for male) associated with reticulocytosis and with markers of haemolysis, i.e., elevated lactate dehydrogenase, low haptoglobin and elevated indirect bilirubin, with a positive direct antiglobulin test (DAT) for IgG with or without complement (C3d) as cold agglutinins are excluded from ES.⁴ Patients with ITP often have repeated infections, easy bruising and bleeding, petechiae, and purpura. Patients with neutropenia frequently experience recurring infections. ITP in patients with Evans syndrome has been found to, in some instances, be severe enough to result in a hemorrhage that poses a significant risk to the patient's life. There have been examples of an elevated risk of ischemia complications caused by AIHA, most often in those older than 60 years of age. These consequences include events linked to acute coronary syndrome or cerebrovascular events.² A history of recurrent miscarriage is a risk factor for secondary ES, which is associated with antiphospholipid syndrome (APS). Antiphospholipid syndrome is a condition of the immune system that causes an increased risk of blood clots, such as thrombosis and/or the loss of a pregnancy. APS may also cause a person to have abnormally low levels of antiphospholipid antibodies (APSA). Antiphospholipid syndrome is brought on by the immune system's production of aberrant antibodies known as antiphospholipid antibodies, which is what gives rise to the condition. Antiphospholipid antibodies are a kind of autoantibody that are directed against proteins that bind phospholipids.^{6,7} If Evans syndrome is suspected after anemia has been diagnosed based on a complete blood count and differential, further workup including levels of lactate dehydrogenase, haptoglobin, bilirubin, and the reticulocyte count is usually required to evaluate for hemolysis. This is the case regardless of whether or not anemia has been diagnosed. Spherocytes on the peripheral smear and a positive direct antiglobulin test (DAT) are further evidence that supports the diagnosis of warm AIHA. Exclusion is necessary in order to diagnose Evans syndrome.^{5,8} Immunoserological examination shows direct antiglobulin test (DAT) +1, immature platelet fraction (IPF) 7.9%. HIV test, anti-HCV and HBSag were non-reactive. Before a diagnosis of Evans syndrome can be made, therefore, it is necessary to rule out common etiologies such as cold agglutinin disease, thrombotic thrombocytopenic purpura (TTP) through careful evaluation of peripheral blood smear, infectious causes (HIV, Hepatitis C), other autoimmune conditions, and malignancies. When a patient is suspected of having secondary Evans syndrome, a battery of diagnostic tests should be undertaken to check for an underlying condition. However, there are no set criteria for which testing should be performed. In young patients who have common illnesses like SLE or ALPS, a basic workup to assess for malignancy, including a chest and abdomen computed tomography scan, should be conducted. This evaluation should look for signs of cancer. The therapy given includes high-dose steroids, antibiotic, blood transfusions and symptomatic therapy. There are currently no clinical trials being conducted for the treatment of ES, and the evidence-based investigations necessary to determine the indications for beginning medication are still in their infancy.⁵ It is hypothesized that steroids limit the capacity of macrophages to remove platelets and erythrocytes from the bloodstream. Prednisolone or prednisone at a dosage of 1–2 mg/kg/day is required to be given in all instances. However, in patients who have severe clinical symptoms, it is advised that an initial dose of 4–6 mg/kg/day be given during the first 72 hours.^{2,9} An initial response rate of around 82%–83% has been observed for patients who are given steroids at a dosage of 1–2 mg/kg/day. The majority of patients have shown a full response after receiving a treatment plan that included a

prednisolone megadose of 30 mg/kg/day for three days, followed by 20 mg/kg/day for four days. This was followed by a gradual tapering to 10, 5, 2, 1 mg/kg/week. Patients need to be reevaluated three weeks after commencing therapy; if a full response is obtained, careful tapering within six months is recommended to minimize unwanted effects.^{5,9}

Patients who have shown a partial response to the prednisolone treatment must maintain the original dosage for a period of two additional weeks in a row. In the event that there is no response, it is imperative to begin the second-line treatment. The reduction in steroid dosage or the presence of viral infections is the most common cause of a lack of response. If there is a high incidence of ITP, IVIG may be administered. There is a correlation between the existence of hepatomegaly and a favorable response in situations where thrombocytopenia is the predominant symptom.^{5,10}

When treating isolated ITP, dexamethasone at a dose of 40 mg per day for four days has been shown to produce a quicker response while maintaining a similar level of effectiveness over the long term. There are currently no data available for AIHA that is isolated, nor for ES-thrombocytopenia or ES-anemia.^{11,12} IVIg should be reserved for individuals with low platelet counts (<30 G/L) and significant bleeding symptoms, best measured by a bleeding score. IVIg are generally given at 1 g/kg on day 1 and repeated on day 3 if the platelet count is below 30 G/L. IVIg can replace steroids as first-line treatment. Corticosteroids may speed up platelet count.^{13,14}

RBC transfusions are necessary in the event that symptomatic anemia is present. During cases of isolated AIHA and ES-anemia, the difficulty is in avoiding the dismissal of alloantibodies that might be obscured by autoantibodies. This is especially important in patients who have recently undergone blood transfusions or in women who have given birth. Because autoantibodies often cause panagglutination of red blood cells (RBC) by targeting antigens that are extensively expressed on RBC, such as glycophorin, protein band 3, and rhesus, certain approaches are required in order to uncover the presence of possible alloantibodies.¹⁵

These approaches rely heavily on autoadsorption since the older methodology, which included diluting the serum, could only identify alloantibodies in 20% of the instances. These newer techniques detect alloantibodies in 100% of the cases. RBC of patient are used in autoadsorption, and these RBC have been previously eluted from being bound by antibodies. After this step, the patient's own serum is added to his RBC, which causes the autoantibodies to become fixed. After adsorption, the serum can be analyzed to determine whether or not it contains alloantibodies. The severity of the anemia makes it more difficult to obtain a sufficient quantity of RBCs, which can make this treatment more difficult to do.¹⁵

It is important to highlight that the procedure should not be carried out on a patient who has received a blood transfusion within the last three months. This is because even a little quantity of transfused RBC is capable of adsorbing alloantibodies, which results in a false negative test. When autoadsorption cannot be performed, a process known as alloadsorption can be carried out with RBC taken from a variety of donors who have been carefully chosen. Nevertheless, this method is labor-intensive and calls for a high level of knowledge, which severely restricts its use.¹⁵

Platelet transfusion is not recommended during isolated ITP and by extension during ES-thrombocytopenia because of the short half-life of platelets after transfusion and the fact that it does not improve outcome in the majority of patients. This is due to the fact that platelet transfusion does not increase the number of platelets in the blood after it has been given to a patient.¹⁶ Platelet transfusions, however, are necessary in the event that life-threatening bleeding occurs, and they must be administered in conjunction with immunomodulatory medications, corticosteroids, and IVIg, in particular.^{17,18}

The median survival of patients with ES has increased over time and is around 7 years. Importantly, the survival is poorer in secondary ES compared to primary ES (1.7 vs. 10.9 years), with a 5-year survival around 75%, which drops to 38% in secondary ES. Overall, the survival is lower than in isolated AIC (8.7 years for isolated AIHA and 12.7 for isolated ITP), and far lower than the general population (21.1 years). Importantly, 30% of deaths occur within the first year of diagnosis, with an adjusted hazard ratio of death of 12.7 at 1 year, 2.3 between 1–5 years, and 1.5 between 5–10 years.^{2,3}

The causes of death are bleedings, with a similar frequency than observed in isolated ITP on the same period, and haematological neoplasms, notably for secondary ES. An increase in mortality was also observed in a large Italian cohort of AIHA with an adjusted hazard ratio of death of 6.8 (95%CI: 1.99–23.63) for ES compared to isolated AIHA. In this study, ES was shown to be a risk factor of death during AIHA, other risk factors being infections, acute renal insufficiency, previous splenectomy, and the need for more than three lines of therapy.^{3,19}

CONCLUSION

Despite multimodal therapy, ES remains a rare, diverse illness with repeated relapses. Its pathophysiology seems to include genetic and epigenetic variables, and understanding its etiology can assist create tailored medicines with fewer side effects, enhancing patients' quality of life. The condition is chronically relapsing and may lead to fatal clinical outcomes with existing treatments. Prospective investigations and clinical trials based on pathophysiology are required to enhance long-term responsiveness and even cure ES.

REFERENCES

- [1]. Jameson J, Fauci A, Kasper D, Hauser S, Longo D, Loscalzo J. Harrison's Principles of Internal Medicine 20th ed. New York NY, McGraw Hill Educ. 2018;
- [2]. Michel M, Chanet V, Dechartres A, Morin A-S, Piette J-C, Cirasino L, et al. The spectrum of Evans syndrome in adults: new insight into the disease based on the analysis of 68 cases. *Blood*. Oktober 2009;114(15):3167–72.
- [3]. Hansen DL, Möller S, Andersen K, Gaist D, Frederiksen H. Evans syndrome in adults-incidence, prevalence, and survival in a nationwide cohort. *Am J Hematol*. 2019;94(10):1081–90.
- [4]. Audia S, Grienay N, Mounier M, Michel M, Bonnotte B. Evans' Syndrome: From Diagnosis to Treatment. Vol. 9, *Journal of Clinical Medicine*. 2020.

- [5]. Jaime-Pérez JC, Aguilar-Calderón PE, Salazar-Cavazos L, Gómez-Almaguer D. Evans syndrome: clinical perspectives, biological insights and treatment modalities. *J Blood Med*. 2018;9:171–84.
- [6]. Giannakopoulos B; Krilis SA. The Pathogenesis of antiphospholipid syndrome. *N Engl J Med*. 2013;368(11):1033–44.
- [7]. Antovic A; Sennstrom M; Bremme K; et al. Obstetric antiphospholipid syndrome. *BMJ J*. 2018;5:197–9.
- [8]. Crowther M, Chan YLT, Garbett IK, Lim W, Vickers MA, Crowther MA. Evidence-based focused review of the treatment of idiopathic warm immune hemolytic anemia in adults. *Blood*. Oktober 2011;118(15):4036–40.
- [9]. Neunert C, Terrell DR, Arnold DM, Buchanan G, Cines DB, Cooper N, et al. American Society of Hematology 2019 guidelines for immune thrombocytopenia. *Blood Adv*. 2019;3(23):3829–66.
- [10]. Chang DK, Yoo DH, Kim TH, Jun JB, Lee IH, Bae SC, et al. Induction of remission with intravenous immunoglobulin and cyclophosphamide in steroid-resistant Evans' syndrome associated with dermatomyositis. *Clin Rheumatol*. 2001;20(1):63–6.
- [11]. Wei Y, Ji X, Wang Y, Wang J, Yang E, Wang Z, et al. High-dose dexamethasone vs prednisone for treatment of adult immune thrombocytopenia: a prospective multicenter randomized trial. *Blood, J Am Soc Hematol*. 2016;127(3):296–302.
- [12]. Mithoowani S, Gregory-Miller K, Goy J, Miller MC, Wang G, Noroozi N, et al. High-dose dexamethasone compared with prednisone for previously untreated primary immune thrombocytopenia: a systematic review and meta-analysis. *Lancet Haematol*. 2016;3(10):e489–96.
- [13]. Godeau B, Chevret S, Varet B, Lefrère F, Zini J-M, Bassompierre F, et al. Intravenous immunoglobulin or high-dose methylprednisolone, with or without oral prednisone, for adults with untreated severe autoimmune thrombocytopenic purpura: a randomised, multicentre trial. *Lancet*. 2002;359(9300):23–9.
- [14]. Khellaf M, Michel M, Schaeffer A, Bierling P, Godeau B. Assessment of a therapeutic strategy for adults with severe autoimmune thrombocytopenic purpura based on a bleeding score rather than platelet count. *Haematologica*. 2005;90(6):829–32.
- [15]. Buetens OW, Ness PM. Red blood cell transfusion in autoimmune hemolytic anemia. *Curr Opin Hematol*. 2003;10(6):429–33.
- [16]. Goel R, Chopra S, Tobian AAR, Ness PM, Frank SM, Cushing M, et al. Platelet transfusion practices in immune thrombocytopenia related hospitalizations. *Transfusion*. 2019;59(1):169–76.
- [17]. Provan D; Gribben JG. *Molecular Hematology*. 3 ed. Singapore: Wiley-Blackwell; 2015.
- [18]. Spahr JE, Rodgers GM. Treatment of immune-mediated thrombocytopenia purpura with concurrent intravenous immunoglobulin and platelet transfusion: a retrospective review of 40 patients. *Am J Hematol*. 2008;83(2):122–5.
- [19]. Barcellini W, Fattizzo B, Zaninoni A, Radice T, Nichele I, Di Bona E, et al. Clinical heterogeneity and predictors of outcome in primary autoimmune hemolytic anemia: a GIMEMA study of 308 patients. *Blood, J Am Soc Hematol*. 2014;124(19):2930–6.