

# GRAFTS COMPARISON BETWEEN QUADRICEPS TENDON AUTOGRAFT VS. ALLOGRAFT FOR ANTERIOR CRUCIATE LIGAMENT REVISION RECONSTRUCTION: A LITERATURE REVIEW

Ariq Muflih Halim Hasibuan<sup>1</sup>, Permana Yudhadibrata<sup>2</sup>

<sup>1</sup>General Practitioner, Haji Medan General Hospital, North Sumatera, Indonesia

<sup>2</sup>Department of Orthopaedic and Traumatology, Haji Medan General Hospital  
North Sumatera, Indonesia

## Corresponding Author:

---

### ABSTRACT

**Introduction:** Anterior cruciate ligament (ACL) reconstruction is one of the most common orthopaedic surgeries performed on active people in the world. One of the most important surgical decisions is graft type for use in the reconstruction. Recently, the quadriceps tendon has gained popularity for use as a graft source for ACL reconstruction. The graft choice is broadly between an autograft or allograft. This review aims to understand the current concepts in graft comparison between quadriceps tendon autograft vs. allograft for anterior cruciate ligament revision reconstruction.

**Methods:** This literature review study was reported following the preferred reporting items for systematic reviews and adhered to a structured review protocol. The author searched the PubMed, ScienceDirect, and British Medical Journal databases. The authors comparing selected publications reporting patient outcomes with all types of reviews or descriptions of ACL revision reconstruction and its graft being used or other related subjects. Published in English is included. The author then formulates a synthesis to support the previously determined research objectives.

**Results:** ACL reconstruction with partial thickness soft tissue quadriceps tendon graft is a reliable option. Where there are differences in the failure rates of ACL reconstructions between allografts and autografts, these can mostly be explained by irradiated grafts. Giving sufficient radiation to achieve sterility will likely weaken grafts and make them more likely to fail; therefore, irradiating grafts is not recommended. The evidence shows no significant differences in clinical effectiveness between autografts and non-irradiated allografts. Failure rates with both grafts are now low.

**Discussion:** The primary goals of rehabilitation after ACL reconstruction do not vary considerably based on graft type and emphasize: (1) restoration of the full range of motion, (2) normalization of quadriceps strength, (3) improvement of overall lower extremity muscle strength, and (4) re-training of movement patterns to return to pre-injury sports participation while decreasing injury risk. Achieving full motion and quadriceps strength contributes to a rapid return to normal weight bearing, gait, and activities of daily living. In the setting of revision ACL reconstruction, there are various considerations regarding graft choice due to tunnel size or position, previous usage of other grafts, and reconstructions in the other leg, which may mean that allografts would be preferred to autografts. The other population not covered sufficiently in the literature is the elite sprinting athlete, where autograft choices may be influenced by the effect of graft harvesting on their sport. However, in most cases, allograft ACL reconstruction with non-irradiated grafts is as safe but more expensive than autograft ACL reconstruction, which is preferred as it is more cost-effective.

**Conclusion:** There is little difference in the results of ACL reconstruction with autografts or non-irradiated allografts, with any advantage being with autografts. The cost is higher with allografts. So if autografts are available, allografts are not cost-effective.

**Keywords:** Grafts, quadriceps tendon, autograft, allograft, anterior cruciate ligament revision reconstruction

## INTRODUCTION

Rupture of the anterior cruciate ligament is a well-known sports injury, with a higher injury incidence in females and those who participate in Level 1 sports. Traditionally, anterior cruciate ligament reconstruction (ACLR) with a bone-patellar tendon-bone (BPTB) or hamstring tendon (HT) autograft has been the preferred surgical procedure for managing complete tears of the anterior cruciate ligament, with a surgeon-preference towards the BPTB as the standard of care.[1] Recently, international utilization of the quadriceps tendon (QT) autograft for primary and revision ACLR has increased in popularity; ACLR with the QT may yield less graft harvest site morbidity than the BPTB and better patient-reported outcomes than the HT. However, revision ACLR outcomes from the Danish Knee Ligament Reconstruction Registry suggests higher graft laxity and failure rates when performing primary ACLR with the QT than both the BPTB and HT; these findings have been debated, along with other literature reporting similar graft survivorship between the QT, BPTB, and HT.[1,2]

Justifying the increased utilization of the QT for ACLR, anatomic and biomechanical studies have highlighted the robust properties of the QT itself, with superior levels of collagen density, length, size, and load-to-failure strength than the BPTB. However, due to the multiple muscular origins of the quadriceps tendon, the QT has the potential for more variation in laminar structure and fiber orientation than the BPTB and HT. This non-uniformity of the quadriceps tendon, along with variation in surgeon skill and reconstruction technique, has been suggested as a reason for the higher QT failure rates within the Danish Knee Ligament Reconstruction Registry.[2]

In addition to intra-graft characteristics, graft-specific considerations for ACLR should also include fixation technique, management of the graft harvest site, and the overall graft ligamentization process. For example, graft fixation with an interference screw may facilitate better graft incorporation than suspensory fixation and reduce the incidence of bone tunnel widening. Regarding the graft harvest site, ACLR with the QT and BPTB may produce more postoperative quadriceps weakness than HT. In contrast, a higher incidence of kneeling-related knee pain has been reported with the BPTB than with both the QT and HT autografts. Lastly, the bone-to-bone healing of the BPTB within the bone tunnels facilitates graft osteointegration, which is a more efficient incorporation process than the fibrovascular healing of an all-soft-tissue graft<sup>35</sup>; these considerations influence surgical decision-making and the rehabilitation plan-of-care, to which the rehabilitation specialist must tailor their exercise prescription to optimize outcomes after ACLR.[3]

Autografts can come from different source tendons. The commonest source now seems to be hamstring tendons, but some surgeons prefer bone-patellar tendon-bone (BPTB) as the first line, and others use BPTB in high-risk patients. Allografts come from various sites, including the tibialis anterior, quadriceps, Achilles tendon, BPTB, and hamstrings (HS). Although previous literature has described rehabilitation considerations for the BPTB and HT autografts, less has been published concerning the QT. The surgeon faces several dilemmas while treating patients with deficient Anterior Cruciate Ligament (ACL).[4]

Once the decision to reconstruct is made, the next critical decision concerns the graft choice. The factors the surgeon considers include donor site morbidity, reported graft failure rates, familiarity with the graft, surgical time, associated complications, ability to restore the patient's activity to pre-injury level, and cost-effectiveness. The graft choice is broadly between an autograft, allograft, or synthetic graft. There have been several studies comparing the outcomes of allografts with autografts. The use of synthetic grafts is becoming very less, considering the associated complications.[3,4] This review aims to understand the current concepts in graft comparison between quadriceps tendon autograft vs. allograft for anterior cruciate ligament revision reconstruction.

## METHODS

This literature review study was reported following the preferred reporting items for systematic reviews and adhered to a structured review protocol. The author searched the PubMed, ScienceDirect, and British Medical Journal databases using the following search strategy: (“Grafts Comparison” OR “Graft Outcome” AND “Quadriceps Tendon” AND “Autograft” AND “Allograft” AND “Anterior Cruciate Ligament” AND “Revision Reconstruction” OR “Treatment” OR “Reconstruction”). The author searches for articles from May 2016 to May 2023

The authors then independently excluded irrelevant articles based on full-text article reviews before comparing selected publications reporting patient outcomes with all types of reviews or descriptions of ACL revision reconstruction and its graft being used or other related subjects. Published in English is included. The author then formulates a synthesis to support the previously determined research objectives.

## RESULTS

### Anatomical and Mechanical Consideration

The QT consists anteriorly of the rectus femoris (RF) fibers, followed by the vastus lateralis and vastus medialis (Fig. 1). The deepest portion, separated by a thin, fat layer, is formed by the vastus intermedius. From the proximal pole of the patella to the myotendinous junction, the QT has an average length of 6–8 cm and ranges in width from 2.5 to 3 cm. With

a relatively constant thickness (the central 10 mm of the quadriceps tendon width at 10 mm, 30 mm, and 60 mm proximal to its insertion is 7.4 mm, 7.4 mm, and 7.1 mm, respectively), the QT is a reliable graft for single anatomic bundle and double-bundle reconstruction.[5]

The vascularity of the quadriceps tendon is built by three arteries (branches of the descending geniculate artery, the lateral circumflex femoral artery, and the medial and lateral superior geniculate arteries). On the medial and lateral sides, the arcades run between the muscular portion of the rectus femoris and the vastus medialis lateral, respectively. The superficial aspect of the tendon has a complete vascular network that extends from the musculotendinous junction to the patella. In contrast, the deep portion has an avascular area of 10 mm proximal to the border of the patella, measuring approximately 30 mm × 15 mm.[6]

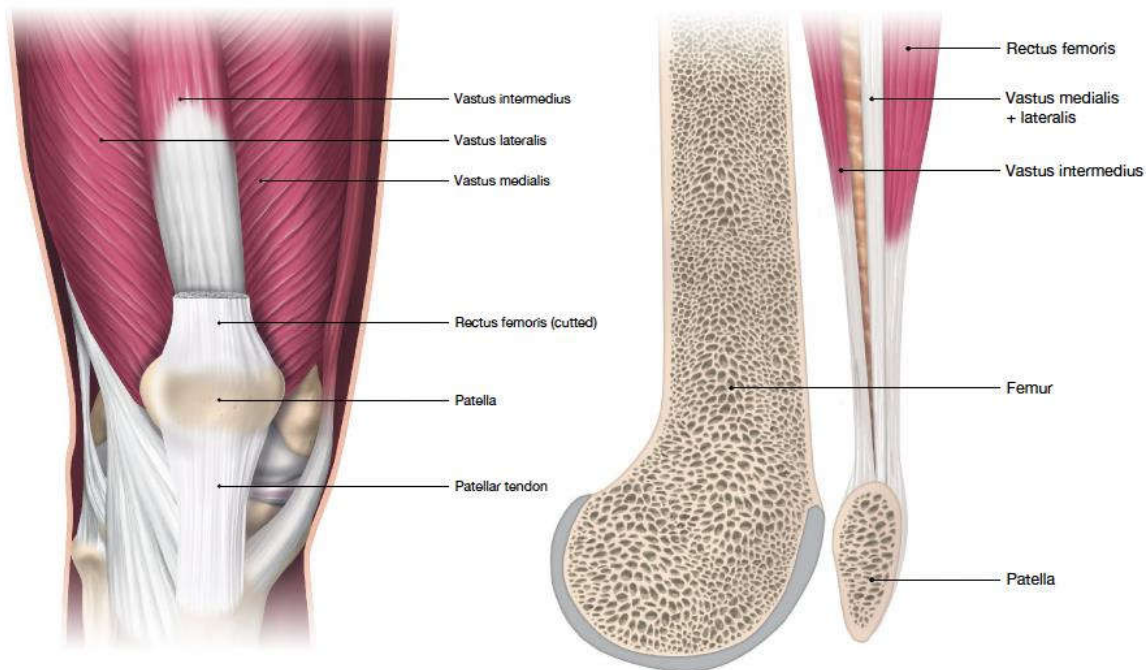


Fig. 1 Anatomy of the quadriceps femoris muscle in frontal and sagittal view

The quadriceps and hamstring tendons differ from the patellar tendon in their innate function to connect muscle to bone, whereas the patellar tendon connects bone to bone. Considering this, differences in stiffness and elastic properties exist between autograft tissue used for ACLR, with the quadriceps tendon producing absolute stiffness than both the patellar and semitendinosus tendons but a lower elastic modulus and relative strain tolerance than the patellar tendon.[1,2]

While these findings reflect total-graft biomechanical properties, previous work has highlighted that regional variation in tendon elasticity and stiffness may also exist; the tendon region closest to the myotendinous junction is less stiff than the tendon region adjacent to the enthesis. This is an important consideration, as biomechanically-induced graft failure studies have reported a difference in failure location for the QT harvested with a patellar bone block (B-QT) than that of the BPTB and multiple-strand HT autografts; failure of the B-QT was most common at the bone-tendon interface, whereas universal stretch/mid-substance failures have been reported with the all soft-tissue QT (S-QT), BPTB and multiple-strand HT. These observations suggest the B-QT has more within-graft variation in regional elasticity and structure, creating increased stress at the bone-tendon interface and the observed graft failure location.[3,4]

Compared to the HT and BPTB, more variation in lamellar structure is present with the QT. In contrast to the continuous structure of the hamstring and patellar tendons, the quadriceps tendon is typically described as a common tendon with a three-layered arrangement; a superficial layer derived from rectus femoris, an intermediate layer from vastus medialis and vastus lateralis, and a deep layer from vastus intermedius. Although the extent to which lamellar structure contributes to graft fixation pull-through is unknown, a biomechanical study reported significant suspensory fixation pull-through with a 150-newton load on the S-QT relative to a bone-block control.[5]

**GRAFT COMPOSITION AND TECHNICAL CONSIDERATIONS**

As mentioned above, the quadriceps tendon autograft is becoming more popular as an autograft option for ACL reconstructions. For the quadriceps tendon harvest, a portion of the proximal patella is taken for a bone plug. The surgeons then harvest the central portion of the quadriceps tendon, including overlying portions of the rectus femoris, vastus medialis, vastus lateralis, and vastus intermedius. This produces a thick, strong graft with a bony plug on one end to fixate when the graft is placed. This allows for bone-to-bone healing and fixation at one end and leaves the patellar tendon

untouched to avoid common donor-site morbidity issues associated with bone-patellar tendon-bone grafts.[7] The quadriceps tendon graft technique is becoming more popular, and its outcomes are increasingly being studied.[8] The remainder of this paper will compare and contrast this surgical option with the ones above in terms of outcomes and rehabilitation implications, as well as discuss a case example of a patient who had this procedure completed (Table 1).

**Table 1. Biomechanical Properties of ACL Graft Options**

Tissue	Load to Failure (N)	Stiffness (N/mm)	Midsubstance Cross-sectional area (mm <sup>2</sup> )	Biological incorporation
QT Autograft	2352	463	71.4±10.5	Bone-to-bone and graft-to-bone healing (6-12 weeks)
QT Allograft	1189	741	105	Bone-to-bone and graft-to-bone healing, slow incorporation (>6 months)

Historically, QT grafts were considered biomechanically inferior to BPTB and HT grafts, but these biomechanical differences may have been due to inferior graft harvesting techniques. These biomechanical tests used a quadriceps tendon–patellar retinaculum–patellar tendon as a graft, which may be weaker and less stiff than the intact ACL, BPTB graft, and HT graft due to the inclusion of the patellar retinaculum. Another technique, the substitution graft technique, uses combined quadriceps and patellar tendon and is associated with persistent quadriceps weakness, especially in females. In contrast, a full-thickness QT harvested with a bone block without the retinaculum has been demonstrated to have an equivalent load to failure compared to BPTB.[5,6]

The harvesting technique of the QT can vary, and along with this, different rehabilitation considerations for graft composition are warranted. The B-QT facilitates partial graft osteointegration as early as 4-6 weeks after ACLR through the bone-to-bone healing of the single bone block within the bone tunnel. Likewise, carries a 1.4-8.8% risk of patellar fracture due to bone block harvest. Conversely, the S-QT is harvested without a patellar bone block and mitigates the risk of patellar fracture. However, the fibrovascular interface will take 10 to 12 weeks to form between the S-QT and the bone tunnels. This between-graft difference in integration, in conjunction with previous research findings, suggests accelerated rehabilitation approaches may be less appropriate for the S-QT fixated with suspensory fixation, especially as graft tension is highly dependent on fixation until biological integration of the graft within the bone tunnels has occurred.[9]

While this is an extrapolated suggestion, short-term increases in graft laxity have been reported with the early introduction of open-kinetic-chain (OKC) quadriceps resistance training after ACLR, to which slightly increased levels of graft laxity were reported with the HT relative to the BPTB when OKC quadriceps resistance training with distal tibial load was initiated between 0-45 degrees of knee flexion weeks 6-12 after ACLR.[10,11]

**DISCUSSION**

**Quadriceps Tendon Autograft vs. Allograft for Anterior Cruciate Ligament Revision Reconstruction**

Three primary studies reported failures and revision rates for allografts and autograft ACL reconstructions. In one RCT at 33–35 months follow-up, the revision rates were similar between groups (allografts 1.6%; autografts 1.5%). The rate of failure requiring revision was statistically significantly higher in the allograft group of the previous RCT than in the autograft group (26.5% and 8.3%, respectively, p = 0.03, duration of follow-up 10.5 years). In the third study, the failure rates at 2.5 years were 2.4% with allografts and 2.2% with autografts. All three studies used fresh-frozen, non-irradiated allografts. The reasons for the higher failure rate are not clear. The operations were done long ago, perhaps when processing methods were more damaging.[12]

Grafts came from a single tissue bank over a relatively short period. Some reviewers have expressed concerns about a higher failure rate in allografts used in patients under 25. A previous study found a higher revision rate in non-irradiated allograft BPTB grafts, but the potential for selection bias in that study was very high. In the large Kaiser Permanente database, an increased failure rate was noted for BPTB allografts compared to autografts which may explain the perceived differences. No statistical difference was seen when autografts were compared to nonprocessed soft tissue allografts in the Kaiser Permanente series, although follow-up remains relatively short for this analysis.[10,11]

The previous studies provide a systematic review of the adverse events after harvesting autografts for ACL reconstruction. They note that in France, most ACL reconstructions are done with autografts taken from hamstring tendons, patellar tendons, and fascia lata. They included 36 articles in a good-quality review. For hamstring autografts, they conclude that there are complications in 8.3% of cases (though some studies have much higher rates). The commonest is saphenous nerve damage, though they think this is largely avoidable by a different approach. Temporary strength deficits (up to 3 months) occur. Because these temporary complications will have an insignificant impact on the long-term economics, they estimate fewer complications with the patellar tendon (PT) grafts (0.2–1.2% overall) but some more serious,

including a patellar fracture in 0.42–1.3%, rupture of PT and anterior knee pain, reported in as many as 46%, but with varying definitions.[12,13]

An evidence review from New Zealand from Accident Compensation Corporation Research has been produced to guide practice. It was based on an overview of 12 systematic reviews. The primary studies were not examined. The last search was done in May 2016, and the reviews were published from 2007 to 2015. The ACC report concluded that there was no evidence of any significant differences in failure rates or other outcomes between autografts and non-irradiated allografts. It concluded that allografts irradiated with low doses still performed less well than non-irradiated allografts and that low doses were insufficient to eliminate the risk of disease transmission.[14]

Given the similar outcomes, cost became the determining factor. Costs of allografts are higher in NZ than elsewhere because there is no local provider. Older studies may need to reflect modern processing methods. Fresh-frozen allografts give better results. Another research found no difference in outcomes between fresh-frozen tibialis posterior allografts and hamstring autografts after 55 months. Previous research reported a meta-analysis showing that BPTB autografts did better than allografts, but the advantage only applied when allografts were irradiated or chemically processed (Table 2).[15,16]

**Table 2. Summary of Indications, Advantages, and Disadvantages of Different ACL Reconstruction Graft Options**

Graft type	Indication	Advantages	Disadvantages	Complications
QT Allograft	<ul style="list-style-type: none"> <li>• Patients aged &gt;40 years</li> <li>• Multi-ligament knee injuries</li> <li>• Patient preference</li> <li>• Previous harvests from other donor sites</li> <li>• Inadequate autograft tissue</li> </ul>	<ul style="list-style-type: none"> <li>• Decreased surgical time</li> <li>• Predictable graft size</li> <li>• Decreased morbidity</li> <li>• Easier recovery</li> <li>• Double-bundle reconstructions</li> <li>• Over-the-top reconstructions</li> <li>• Multiple types of allografts available (e.g., patellar tendon, tibialis anterior or posterior,</li> <li>• Hamstrings, personals, iliotibial band, and Achilles tendon)</li> </ul>	<ul style="list-style-type: none"> <li>• Cost</li> <li>• Infectious disease transmission</li> <li>• Delayed incorporation</li> <li>• Higher failure rate (up to 25%)</li> <li>• Lower return to-sport rate compared with autograft (43.3% versus 75%)</li> </ul>	<ul style="list-style-type: none"> <li>• Infection</li> <li>• Intraoperative fracture of allograft bone, given its softness</li> </ul>
QT Autograft	<ul style="list-style-type: none"> <li>• Young, athletic individuals who are skeletally mature or immature (no bone block)</li> <li>• ACL with a large footprint (&gt;16 mm)</li> <li>• Athletes who rely on their HSs (sprinters)</li> <li>• Athletes or laborers who spend time on their knees (e.g., wrestlers, judo, and carpenters)</li> </ul>	<ul style="list-style-type: none"> <li>• Reliable and robust graft (cross-sectional area 62 mm<sup>2</sup>)</li> <li>• It can be used with or without bone block</li> <li>• Less risk of infection compared with HS</li> <li>• Less risk of injury to the infra saphenous branch (1.5% versus 53.3% in BTB)</li> <li>• Low donor site morbidity (zero-15% versus</li> </ul>	<ul style="list-style-type: none"> <li>• Prolonged quadriceps weakness with full-thickness grafts</li> <li>• Donor site pain</li> <li>• Fluid extravasation during arthroscopy</li> </ul>	<ul style="list-style-type: none"> <li>• Postoperative hematoma</li> <li>• Patellar fracture with bone block harvest</li> <li>• Rectus femoris retraction</li> </ul>

- 18%-51% in BTB)
- Less anterior knee pain (4.6% versus 26.7% in BTB)
- Can be harvested minimally invasively

Where there are differences in the failure rates of ACL reconstructions between allografts and autografts, these can mostly be explained by irradiated grafts. Giving sufficient radiation to achieve sterility will likely weaken grafts and make them more likely to fail; therefore, irradiating grafts is not recommended. The evidence shows no significant differences in clinical effectiveness between autografts and non-irradiated allografts. Failure rates with both grafts are now low. BPTB allografts have been described as having higher failure rates in some studies than autografts. However, this is not the case for soft tissue allografts, with only one RCT showing a difference between soft tissue allografts and autografts. In contrast, the majority of RCTs had very similar failure rates. Previous RCTs that showed a difference had an unusually high allograft failure rate of 27%. The reasons for this need to be clarified. The operations were done long ago when processing methods were more damaging. Grafts came from a single tissue bank over a relatively short period.[13–15]

Failure does not necessarily mean something is wrong with the procedure or the technology. It should be noted that people having these procedures do so because they have damaged or ruptured their tissues, perhaps by putting great demands on the knee structures, often during sport. When an intervention has a higher cost than the comparator but is no more clinically effective or less effective, it is said to be "dominated" in cost-effectiveness analysis, as is the case with allografts in this study. Costs with allografts are higher because of the graft cost, and the cost we used may be less than that in other countries. The findings of the economic modeling need to consider the local costs of the graft, but this can be done based on the data shown here, as the cost of the graft was the dominant factor in the economic model.[17,18]

There is less morbidity with allografts because they are not harvested from the live patient, but the disutility is transient and insufficient to change the overall conclusion on cost-effectiveness. Previous research specifically reviewed the adverse events after harvesting autografts for ACL reconstruction. For hamstring autografts, they conclude that there are complications in 8.3% of cases; the commonest is saphenous nerve damage. Temporary strength deficits (up to 3 months) occur. Because these temporary complications will have an insignificant impact on the long-term economics.[19,20] Revision ACL reconstruction is also an effective operation, using the hamstring or BPTB graft from either the same or the other leg. This study was not directly designed to compare allograft and autograft usage for revision ACL reconstruction. However, a literature review shows no difference in failure rate between allograft and autograft revision ACL reconstruction; therefore, the allograft cost will continue to dominate the economic analysis.[17,18]

There may be situations in which allografts should be considered. The review has assumed that a direct choice can be made between allografts and autografts and that both are available. There may be situations where a satisfactory autograft is unavailable, for example, in multi-ligament injury, where available autografts will be used for other reconstructions. Also, in the setting of revision ACL reconstruction, there are various considerations regarding graft choice due to tunnel size or position, previous usage of other grafts, and reconstructions in the other leg, which may mean that allografts would be preferred to autografts. The other population not covered sufficiently in the literature for us to conclude is the elite sprinting athlete, where autograft choices may be influenced by the effect of graft harvesting on their sport. However, in most cases, allograft ACL reconstruction with non-irradiated grafts is as safe but more expensive than autograft ACL reconstruction, which is preferred as it is more cost-effective.[20,21]

### **Rehabilitation After Quadriceps Tendon Autograft Vs. Allograft In ACL Reconstruction**

The primary goals of rehabilitation after ACL reconstruction do not vary considerably based on graft type and emphasize: (1) restoration of the full range of motion, (2) normalization of quadriceps strength, (3) improvement of overall lower extremity muscle strength, and (4) re-training of movement patterns to return to pre-injury sports participation while decreasing injury risk. Achieving full motion and quadriceps strength contributes to a rapid return to normal weight bearing, gait, and activities of daily living. Autograft-specific considerations aim to decrease the morbidity associated with harvest. After QT, the interventions are targeted to improve the RF strength and the QT's load tolerance.[22]

Early after QT harvest for ACL reconstruction (ACLR with QT), the harvest site can be treated like a tendinopathy. The tendon can be loaded through stretching and isometric exercises targeting the RF. Exercises should consider the hip and pelvis position, as the RF originates on the anterior inferior iliac spine and terminates at the patella. After ACLR with QT, exercises should be performed with the hip in neutral or slight extension and the knee in various degrees of flexion to ensure the entire RF muscle–tendon unit is placed on tension. The modified Thomas Test position is optimal for creating a hip extension and knee flexion while allowing the patient to relax. Stretching may be limited early as knee flexion is limited, but motion at the hip may be used to increase the load on the RF and QT.[23,24]

An inferior patellar mobilization may also be added in this position to increase the targeted stretch to the quadriceps tendon. Stretch intensity should not cause lasting pain or soreness. When performing isometric quadriceps exercises in the early stages after ACLR with QT, the goal should be to activate the quadriceps while creating tension within the harvest site. Active tension in the harvest site will promote the remodeling of the tendon as long as the tension is not too high to the point of tissue damage or overload. Each patient will have a slightly different position that creates the desired tension, and therefore, a quadriceps isometric matrix to describe the positions is proposed for use.[25]

In later phases of rehabilitation, restoration of quadriceps strength symmetry is the key before agility training, sport-specific training, and return to running and sports. Published strength outcomes after ACLR with QT are sparse and conflicting. Retrospective reviews with 1-year outcomes after ACLR with QT indicate that average quadriceps limb symmetry is between 82 and 85%, and many individuals present with quadriceps deficits greater than 10%. Published prospective short-term results (6–23 months after surgery) show that more than 50% of participants have not achieved the recommended 80% symmetry after either QT or BTB autograft but do indicate these results were less likely related to neuromuscular deficits than to pure strength deficits.[24–26]

Preliminary results indicate that in the late rehabilitation phase, quadriceps strength symmetry after full-thickness QT ( $69.5\% \pm 17.4\%$ ) is poor when compared to BPTB autografts ( $82.8\% \pm 14.6\%$ ) and HT autograft ( $86.0\% \pm 18.6\%$ ). More important, only 26% of patients with QT autograft achieved the desired 80% quadriceps strength symmetry in the 5–8 month postoperative period. Results improved in the 9–15 month follow-up but were still sub-optimal. These results prompted the changes to our muscle rehabilitation approach and a switch to a less invasive partial thickness graft harvest.[27]

### Complications And Outcomes After Quadriceps Tendon Autograft Vs. Allograft In ACL Reconstruction

Individualized ACL reconstruction relies on matching the characteristics of the graft to the native anatomy of the patient and determining which complication profile can be best tolerated by the patient. Despite the relative advantages of QT over BPTB or HT autograft, complications arise following QT graft harvesting. Donor site pain has been reported but is less common than in BPTB in a comparative trial. Post-operatively, the QT limb is also weaker than the contralateral side by around 15% in men and 30% in women. As discussed previously, the QT has a rich blood supply, which can predispose patients to postoperative hematoma. This risk can be minimized through careful dissection and avoiding the muscular junction. Retraction of the RF following QT has been published as an isolated event. However, it has yet to be reported in most studies, so this complication rate after QT harvest is still being determined. Fractures of the patella following QT + BB harvest have also been reported.[25–27]

A systematic review of QT vs. BPTB and HT shows no significant differences in patient-reported outcomes or laxity restoration between QT and either BPTB or HS. Patient satisfaction with the result of the procedure is also similar between QT and BPTB. Measures of knee stability, including KT-1000 arthrometer, subjective pivot shift rating, and Lachman testing, have not shown significant differences at final follow-up between QT and either BPTB or HS autograft. However, a recent registry study demonstrated higher revision rates for ACLR with QT than HT and BPTB (4.7 vs. 2.3 vs. 1.5%). 531 QT, 14,213 HT, and 1835 PT ACLR were analyzed between 2005 and 2017. This study used QT in only 3.2% of all ACL reconstructions, and graft size, bone block use, or fixation technique is not available. Overall, QT autograft has lower rates of acute and chronic morbidity compared to HT and BPTB tendon harvest with equivalent patient outcomes and rates of graft failure.[28,29]

### CONCLUSION

There is little difference in the results of ACL reconstruction with autografts or non-irradiated allografts, with any advantage being with autografts. The cost is higher with allografts. So if autografts are available, allografts are not cost-effective. ACL reconstruction with partial thickness soft tissue quadriceps tendon graft is a reliable option in top-level athletes. Compared to BPTB and HT grafts, less kneeling pain, anterior knee pain, and less weakened knee flexion have been described, but with no difference in clinical outcome and failure rate. From an anatomical point of view, a full-thickness graft can be harvested if necessary, but after full-thickness harvest, the quadriceps strength symmetry is weak in the follow-up compared to BPTB or HT grafts. Therefore, a partial thickness graft may be more beneficial concerning rehabilitation and return to sport. With a focus on soccer, a partial thickness QT ACL reconstruction is recommended, followed by a staged progressive rehabilitation, including training with a ball as early in the rehabilitation process as possible to optimize outcomes in top-level athletes.

### REFERENCES

- [1] Prince J, Xerogeanes J. *Clinical Outcomes of All-Soft Tissue Quadriceps Tendon Autograft for Revision Anterior Cruciate Ligament Reconstruction.*; 2021.
- [2] Runer A, Keeling L, Wagala N, et al. Current trends in graft choice for anterior cruciate ligament reconstruction – part I: anatomy, biomechanics, graft incorporation and fixation. *J Exp Orthop.* 2023;10(1). doi:10.1186/s40634-023-00600-4
- [3] Dheerendra SK, Khan WS, Singhal R, Shivarathre DG, Pydisetty R, Johnstone D. *Anterior Cruciate Ligament Graft Choices: A Review of Current Concepts.* Vol 6.; 2020.

- [4] Mayr HO, Willkomm D, Stoehr A, et al. Revision of anterior cruciate ligament reconstruction with patellar tendon allograft and autograft: 2- and 5-year results. *Arch Orthop Trauma Surg.* 2022;132(6):867-874. doi:10.1007/s00402-012-1481-z
- [5] Kwak YH, Lee S, Lee MC, Han HS. Anterior cruciate ligament reconstruction with quadriceps tendon-patellar bone allograft: Matched case control study. *BMC Musculoskelet Disord.* 2018;19(1). doi:10.1186/s12891-018-1959-0
- [6] Meena A, D'Ambrosi R, Runer A, et al. Quadriceps tendon autograft with or without bone block have comparable clinical outcomes, complications and revision rate for ACL reconstruction: a systematic review. *Knee Surgery, Sports Traumatology, Arthroscopy.* Published online 2022. doi:10.1007/s00167-022-07281-z
- [7] Pascual-Garrido C, Carbo L, Makino A. Revision of anterior cruciate ligament reconstruction with allografts in patients younger than 40 years old: A 2 to 4 year results. *Knee Surgery, Sports Traumatology, Arthroscopy.* 2018;22(5):1106-1111. doi:10.1007/s00167-013-2507-y
- [8] Legnani C, Zini S, Borgo E, Ventura A. Revision anterior cruciate ligament reconstruction with contralateral hamstring tendon grafts: 6 years follow-up. *Joints.* 2017;5(1):17-20. doi:10.1055/s-0037-1601410
- [9] Runer A, Suter A, Roberti di Sarsina T, et al. Quadriceps tendon autograft for primary anterior cruciate ligament reconstruction show comparable clinical, functional, and patient-reported outcome measures, but lower donor-site morbidity compared with hamstring tendon autograft: A matched-pairs study with a mean follow-up of 6.5 years. *Journal of ISAKOS.* Published online April 1, 2023. doi:10.1016/j.jisako.2022.08.008
- [10] Hurley ET, Calvo-Gurry M, Withers D, Farrington SK, Moran R, Moran CJ. Quadriceps Tendon Autograft in Anterior Cruciate Ligament Reconstruction: A Systematic Review. *Arthroscopy - Journal of Arthroscopic and Related Surgery.* 2018;34(5):1690-1698. doi:10.1016/j.arthro.2018.01.046
- [11] Cavaignac E, Coulin B, Tscholl P, Nik Mohd Fatmy N, Duthon V, Menetrey J. Is Quadriceps Tendon Autograft a Better Choice Than Hamstring Autograft for Anterior Cruciate Ligament Reconstruction? A Comparative Study with a Mean Follow-up of 3.6 Years. *American Journal of Sports Medicine.* 2017;45(6):1326-1332. doi:10.1177/0363546516688665
- [12] Myer DM, Wright KL. *Graft Options in Anterior Cruciate Ligament Reconstruction: A Patient's Guide.*; 2020.
- [13] Pichler L, Pichler L, Liu M, et al. Functional Outcome of All-Soft-Tissue Quadriceps Tendon Autograft in ACL Reconstruction in Young and Athletic Patients at a Minimum Follow-Up of 1 Year. *J Clin Med.* 2022;11(22). doi:10.3390/jcm11226706
- [14] Lind M, Strauss MJ, Nielsen T, Engebretsen L. Quadriceps tendon autograft for anterior cruciate ligament reconstruction is associated with high revision rates: results from the Danish Knee Ligament Registry. *Knee Surgery, Sports Traumatology, Arthroscopy.* 2020;28(7):2163-2169. doi:10.1007/s00167-019-05751-5
- [15] Ellis HB, Matheny LM, Briggs KK, Pennock AT, Steadman JR. Outcomes and revision rate after bone-patellar tendon-bone allograft versus autograft anterior cruciate ligament reconstruction in patients aged 18 years or younger with closed physes. *Arthroscopy - Journal of Arthroscopic and Related Surgery.* 2021;28(12):1819-1825. doi:10.1016/j.arthro.2021.06.016
- [16] Buerba RA, Boden SA, Lesniak B. Graft Selection in Contemporary Anterior Cruciate Ligament Reconstruction. *JAAOS: Global Research and Reviews.* 2021;5(10). doi:10.5435/JAAOSGlobal-D-21-00230
- [17] Xerogeanes JW. Quadriceps Tendon Graft for Anterior Cruciate Ligament Reconstruction: THE GRAFT OF THE FUTURE! *Arthroscopy - Journal of Arthroscopic and Related Surgery.* 2019;35(3):696-697. doi:10.1016/j.arthro.2019.01.011
- [18] Bastidas MVP, Sastre S, Vilalta JMS, Rios J, Sabater M, Popescu D. Quadriceps tendon vs hamstring autograft in primary ACL reconstruction – a comparative study with minimum two-year follow-up. *Acta Orthop Belg.* 2022;88(2):347-354. doi:10.52628/88.2.7306
- [19] Solie B, Monson J, Larson C. Graft-Specific Surgical and Rehabilitation Considerations for Anterior Cruciate Ligament Reconstruction with the Quadriceps Tendon Autograft. *Int J Sports Phys Ther.* 2023;18(2):493-512. doi:10.26603/001c.73797
- [20] Thompson L. *Quadriceps Tendon Graft for ACL Reconstruction - How Does It Compare? - A Literature Review with a Case Example.*; 2018.
- [21] Aslam MA, Avasthi S, Aggarwal P, Singh S, Kumar V, Mahapatra S. Clinical Outcomes of Anterior Cruciate Ligament Reconstruction Using Quadriceps Tendon Autograft Versus Hamstring Tendons Autograft: A Retrospective Analysis. *Cureus.* Published online October 14, 2021. doi:10.7759/cureus.18760
- [22] Heffron WM, Hunnicutt JL, Xerogeanes JW, Woolf SK, Slone HS. Systematic Review of Publications Regarding Quadriceps Tendon Autograft Use in Anterior Cruciate Ligament Reconstruction. *Arthrosc Sports Med Rehabil.* 2019;1(1):e93-e99. doi:10.1016/j.asmr.2019.09.001



- [23] Vilchez-Cavazos F, Dávila-Martínez A, Garza-Castro SD La, et al. Anterior cruciate ligament injuries treated with quadriceps tendon autograft versus hamstring autograft: A randomized controlled trial. *Cirugia y Cirujanos (English Edition)*. 2020;88(1):76-81. doi:10.24875/CIRU.19001001
- [24] Baawa-Ameyaw J, Plastow R, Begum FA, Kayani B, Jeddy H, Haddad F. Current concepts in graft selection for anterior cruciate ligament reconstruction. *EFORT Open Rev*. 2021;6:808-815. doi:10.1302/2058-5241.6.210023
- [25] Mistry H, Metcalfe A, Colquitt J, et al. Autograft or allograft for reconstruction of anterior cruciate ligament: a health economics perspective. *Knee Surgery, Sports Traumatology, Arthroscopy*. Published online 2019. doi:10.1007/s00167-019-05436-z
- [26] Mo Z, Li D, Yang B, Tang S. Comparative Efficacy of Graft Options in Anterior Cruciate Ligament Reconstruction: A Systematic Review and Network Meta-Analysis. *Arthrosc Sports Med Rehabil*. 2020;2(5):e645-e654. doi:10.1016/j.asmr.2020.05.007
- [27] Yoshida A, Yamamoto M, Li-Tsang CWP, Iwatsuki K, Hirata H. A systematic review assessing the effectiveness of hand therapy programmes in adults with burns using the International Classification of Functioning, Disability and Health framework. *Nagoya J Med Sci*. 2022;84(4):689-704. doi:10.18999/nagjms.84.4.689
- [28] Hogan DW, Burch MB, Rund JM, et al. No Difference in Complication Rates or Patient-Reported Outcomes Between Bone–Patella Tendon–Bone and Quadriceps Tendon Autograft for Anterior Cruciate Ligament Reconstruction. *Arthrosc Sports Med Rehabil*. 2022;4(2):e417-e424. doi:10.1016/j.asmr.2021.10.019
- [29] Diermeier T, Tisherman R, Hughes J, et al. Quadriceps tendon anterior cruciate ligament reconstruction. *Knee Surgery, Sports Traumatology, Arthroscopy*. 2020;28(8):2644-2656. doi:10.1007/s00167-020-05902-z