

CORTICOSTEROID AND LIDOCAIN INJECTION FOR TREATMENT OF HIP OSTEOARTHRITIS : AN UPDATE SYSTEMATIC REVIEW

^{1*}M. Yudhi Hardiyansah, ²Yosie Yulanda Putra, ³Ahsan Auliya

^{1*}Faculty of Medicine, Malahayati University, Indonesia

²H. Bakri Sungai Penuh General Hospital, Indonesia

³Pertamedika Baiturrahim General Hospital, Indonesia

Correspondence Author:

yudyhardiyansah@yahoo.co.id

ABSTRACT

Background: Intraarticular corticosteroid injections (ICSI) can relieve pain in patients with symptomatic osteoarthritis (OA) for weeks. A recent randomized controlled trial showed superior pain improvement following ICSI compared to treatment without injection over a period of 6 months. Atchia et al. compared ICSI to saline-injection and treatment without injection and found ICSI to be the only treatment resulting in significant improvement in both pain and function.

The aim: The aim of this study to show about corticosteroid and lidocaine injection for treatment of hip osteoarthritis.

Methods: By the Preferred Reporting Items for Systematic Review and Meta-Analysis (PRISMA) 2020, this study was able to show that it met all of the requirements. This search approach, publications that came out between 2014 and 2024 were taken into account. Several different online reference sources, like Pubmed, SagePub, and Google Scholar were used to do this. It was decided not to take into account review pieces, works that had already been published, or works that were only half done.

Result: In the PubMed database, the results of our search get 7 articles, whereas the results of our search on SagePub get 6 articles, on Google Scholar 1690 articles. Records remove before screening are 1438, so we get 265 articles for screening. After we screened based on record exclude, we compiled a total of 10 papers. We included five research that met the criteria.

Conclusion: Ultrasound guided intra-articular hip injection of corticosteroid and local anaesthetic, administered with advice and education, is a clinically effective treatment for rapid and sustained symptom response compared with advice and education alone for people with hip osteoarthritis. These findings provide evidence to inform international guidelines and support treatment decision making for policy makers, payers (commissioners), GPs, and clinicians in musculoskeletal services.

Keyword: Osteoarthritis, hip osteoarthritis, corticosteroid, lidocaine.

INTRODUCTION

Intra-articular corticosteroid/anesthetic injection (CSI) is a common treatment for osteoarthritis (OA) of the hip. It has been shown to have significantly greater short-term pain and functional improvements over placebo in multiple randomized controlled trials. However, there are relatively few high-level studies that investigate complications of hip CSI. In vitro studies have shown that single doses of both local anesthetic and corticosteroids result in significant chondrocyte cytotoxicity; however, this has not yet been shown clinically. Two placebo-controlled, randomized controlled trials have investigated the effect of knee CSI on articular cartilage and have demonstrated conflicting results: Raynauld et al found no difference in radiographic arthritis at 12 and 24 months between the CSI and placebo groups, whereas McAlindon et al found that the CSI group had 0.11 mm more cartilage thinning on magnetic resonance imaging (MRI) relative to the placebo group at 24 months. Although MRI better detects cartilage thinning than does radiography, no minimal clinically important difference in MRI-determined cartilage thinning has been established.^{1,2}

Hip osteoarthritis (OA) is a chronic condition characterized by structural damage of the entire joint including inflammation of the synovial membrane, progressive erosion of the articular hyaline cartilage, and degeneration of the joint capsule and musculotendinous structures. The incidence of symptomatic hip OA is estimated to be about 25% of life, and its prevalence is increasing due to the aging of the global population and the rise in obesity. Although pain is the predominant clinical presentation, it also often severely affects daily activities and leads to societal cost.³

Hip OA management primarily focuses on rapid symptom control including pain alleviation and functional improvement. The treatment approach for hip OA relies on a combination of non-pharmacological and pharmacological therapies consisting of lifestyle modification, physical therapy, and non-steroidal anti-inflammatory drugs. Primary total hip arthroplasty is an intervention reserved for cases that do not respond efficiently to appropriate approaches for a reasonable period of time. However, even after a properly performed total joint replacement, up to 38% of patients have permanent disability and persistent postsurgical pain after 1 year. Since implant longevity in the younger population is a contentious topic, and complications due to older age or comorbidities, non-operative treatment options are of interest and are being explored in hip OA.^{3,4}

Conservative management of OA relies on a combination of nonpharmacological and pharmacological modalities. Among those, intraarticular (IA) corticosteroid (CS) injections have been used for many decades, with the first report of IA CS use dating back to 1940; the practice was then established by Hollander in 1951. Nowadays, they have become commonly recommended in the management of large joint osteoarthritis, including the hip. However, there are rather few studies addressing IA CS injections in hip OA while the subject has been extensively studied in the knee. Thus, it appears important to review the real efficacy and tolerability of IA CS injections in hip OA.^{5,6}

METHODS

Protocol

By following the rules provided by Preferred Reporting Items for Systematic Review and Meta-Analysis (PRISMA) 2020, the author of this study made certain that it was up to par with the requirements. This is done to ensure that the conclusions drawn from the inquiry are accurate.

Criteria for Eligibility

For the purpose of this literature review, we compare and contrast corticosteroid and lidocaine injection for treatment of hip osteoarthritis. It is possible to accomplish this by researching or investigating corticosteroid and lidocaine injection for treatment of hip osteoarthritis. As the primary purpose of this piece of writing, demonstrating the relevance of the difficulties that have been identified will take place throughout its entirety.

In order for researchers to take part in the study, it was necessary for them to fulfil the following requirements: 1) The paper needs to be written in English, and it needs to determine about corticosteroid and lidocaine injection for treatment of hip osteoarthritis. In order for the manuscript to be considered for publication, it needs to meet both of these requirements. 2) The studied papers include several that were published after 2014, but before the time period that this systematic review deems to be relevant. Examples of studies that are not permitted include editorials, submissions that do not have a DOI, review articles that have already been published, and entries that are essentially identical to journal papers that have already been published.

Search Strategy

We used "corticosteroid and lidocaine injection for treatment of hip osteoarthritis." as keywords. The search for studies to be included in the systematic review was carried out using the PubMed and SagePub databases by inputting the words: *("Corticosteroids"[MeSH Subheading] OR "steroid"[All Fields] OR "Lidocaine [All Fields]) AND ("Osteoarthritis"[All Fields] OR "Hip osteoarthritis"[All Fields]) AND ("Management of osteoarthritis"[All Fields]) OR ("Management of hip osteoarthritis" [All Fields])* used in searching the literature.

Data retrieval

After reading the abstract and the title of each study, the writers performed an examination to determine whether or not the study satisfied the inclusion criteria. The writers then decided which previous research they wanted to utilise as sources for their article and selected those studies. After looking at a number of different research, which all seemed to point to the same trend, this conclusion was drawn. All submissions need to be written in English and cannot have been seen anywhere else.

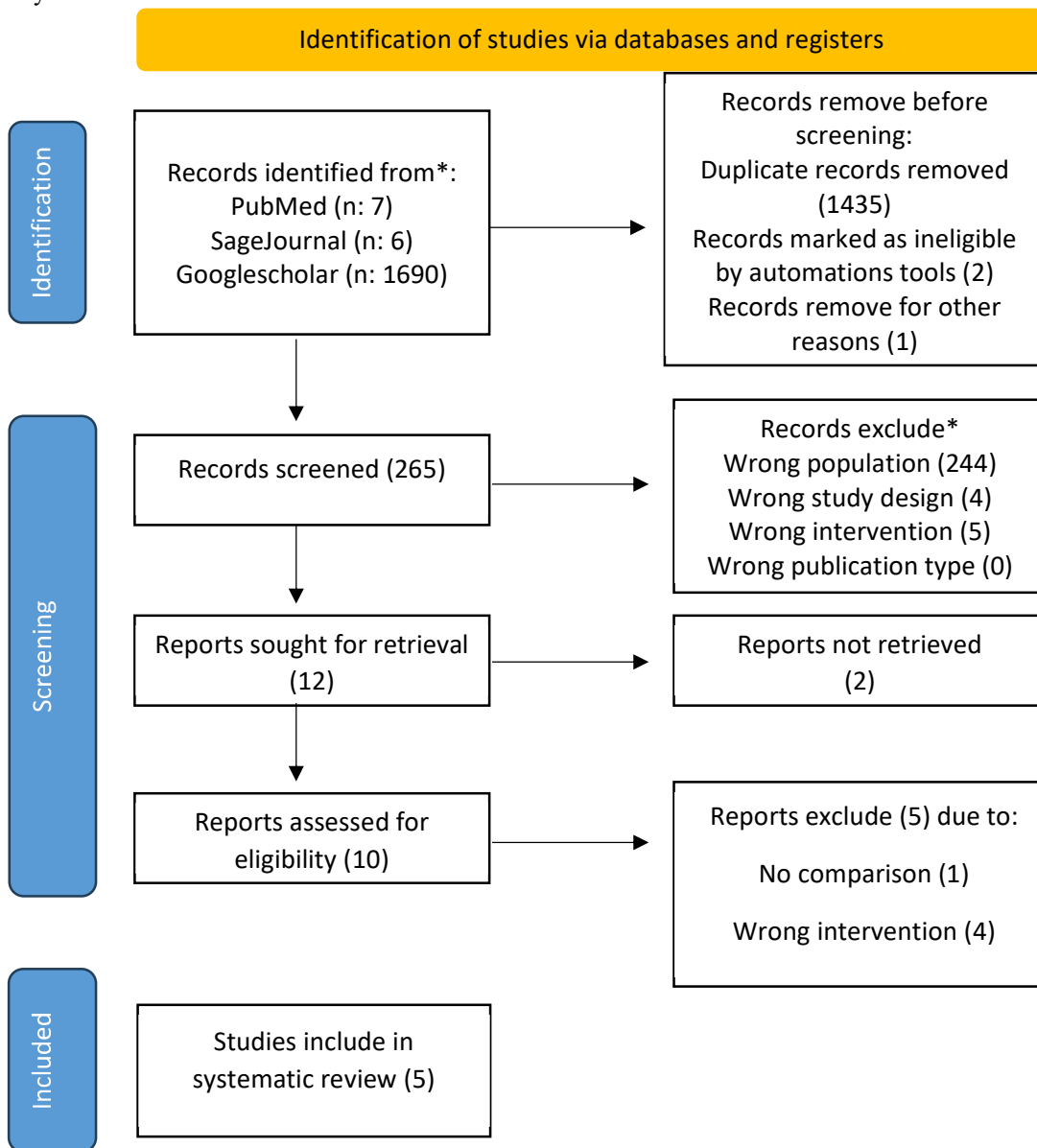


Figure 1. Article search flowchart

Only those papers that were able to satisfy all of the inclusion criteria were taken into consideration for the systematic review. This reduces the number of results to only those that are pertinent to the search. We do not take into consideration the conclusions of any study that does not satisfy our requirements. After this, the findings of the research will be analysed in great detail. The following pieces of information were uncovered as a result of the inquiry that was carried out for the purpose of this study: names, authors, publication dates, location, study activities, and parameters.

Quality Assessment and Data Synthesis

Each author did their own study on the research that was included in the publication's title and abstract before making a decision about which publications to explore further. The next step will be to evaluate all of the articles that are suitable for inclusion in the review because they match the criteria set forth for that purpose in the review. After that, we'll determine which articles to include in the review depending on the findings that we've uncovered. This criteria is utilised in the process of selecting papers for further assessment. In order to simplify the process as much as feasible when selecting papers to evaluate. Which earlier investigations were carried out, and what elements of those studies made it appropriate to include them in the review, are being discussed here.

RESULT

From the PubMed database, the results of our search get 7 articles, whereas the results of our search on SagePub get 6 articles, on Google Scholar 1690 articles. Records remove before screening are 1438, so we get 265 articles for screening. After we screened based on record exclude, we compiled a total of 10 papers. We included five research that met the criteria.

Backhouse, MR et al (2023)⁷ showed Multiple professional groups regularly administer intra-articular corticosteroids for symptomatic first MTPJ OA across a range of NHS healthcare settings. Overall, methylprednisolone acetate was the most commonly administered steroid and lidocaine hydrochloride the most common local anaesthetic. There was large variation in the use of imaging guidance, type and dose of steroid, local anaesthetic, and clinical pathways used in the intra-articular injection of corticosteroids for people with first MTPJ OA.

Streck, LE et al (2023)⁸ showed the rate of RPIO was 0.6%. The current findings suggest that if ICSI is performed under sterile conditions, the risk for septic arthritis or PJI following THA, even in patients with multiple ICSI or ICSI within 3 months prior to surgery, is minimal.

Table 1. The literature include in this study

Author	Origin	Method	Sample Size	Result
Backhouse, MR et al., 2023 ⁷	UK	A cross-sectional survey using Qualtrics online survey platform (Qualtrics, Provo, UT, USA), distributed through professional bodies, special interest groups, and social media.	150	One hundred forty-four healthcare professionals responded, including podiatrists (53/144; 39%), orthopaedic surgeons (28/144; 19%), podiatric surgeons (26/144; 17%) and physiotherapists (24/144; 16%). Half of respondents administered up to 25 corticosteroid injections per year (67/136; 49%) but some administered more than fifty (21/136; 15%). Injections were administered across the healthcare system but were most common in hospital settings (64/136; 44%) followed by community (38/136; 26%), with less delivered in primary care (11/136; 8%). Half of respondents routinely used image-guidance, either ultrasound or x-ray/fluoroscopy (65/136; 48%) although over one third used none (52/136; 38%). Imaging guidance was more common amongst medical professionals (21/31; 68%) compared to non-medical health professionals (45/105; 43%).
Streck, LE et al., 2023 ⁸	USA	This is a retrospective evaluation of 682 hips that underwent ICSI with 40 mg of Triamcinolone for primary osteoarthritis of the hip. All ICSI were performed using sterile	638	4 hips (0.6%) developed RPIO 2–4 months following ICSI. The cumulative Triamcinolone dose was not associated with the development of RPIO (p=0.281). 1 case was diagnosed with septic arthritis and treated with staged THA, there were no signs of infection at a 5 years follow-up. 483 hips (75.7%) underwent THA, including 199 hips with THA

		techniques, the number of ICSI in each hip and the cumulative corticosteroid dosage were assessed. Pre- and post-injection radiographs were compared to identify cases with RPIO. Native joint septic arthritis, surgical site infections and PJI were identified by chart review.		less than 3 months following ICSI and 181 hips with >1 ICSI prior to THA. There were 3 superficial surgical site infections/wound dehiscence and no PJI.
Paskins, Z et al., 2022⁹	UK	The Hip Injection Trial (HIT), a pragmatic, three arm, parallel group, single blind, randomised controlled trial, was conducted within the National Health Service in two community based musculoskeletal services in England. The trial included a linked qualitative study and economic analysis (both reported separately).	199	Mean age of the study sample was 62.8 years (standard deviation 10.0) and 113 (57%) were women. Average weighted follow-up rate across time points was 93%. Greater mean improvement in hip pain intensity over six months was reported with BCT plus ultrasound-triamcinolone-lidocaine compared with BCT: mean difference -1.43 (95% confidence interval -2.15 to -0.72), P<0.001; standardised mean difference -0.55 (-0.82 to -0.27). No difference in hip pain intensity over six months was reported between BCT plus ultrasound-triamcinolone-lidocaine compared with BCT plus ultrasound-lidocaine (-0.52 (-1.21 to 0.18)). The presence of ultrasound confirmed synovitis or effusion was associated with a significant interaction effect favouring BCT plus ultrasound-triamcinolone-lidocaine (-1.70 (-3.10 to -0.30)). One participant in the BCT plus ultrasound-triamcinolone-lidocaine group with a bioprosthetic aortic valve died from subacute bacterial endocarditis four months after the intervention, deemed possibly related to the trial treatment.
Cushman, DM et al., 2020¹⁰	USA	An electronic survey was sent to 3,400 members of the AMSSM. Demographic	674	Most respondents used triamcinolone (50-56% of physicians, depending on injection location) or methylprednisolone (25-29% of physicians), 21-40mg (53-

		variables were collected: primary specialty (residency), training location, practice location, years of clinical experience, current practice type, and rationale for choosing an injectate.		60% of physicians), diluted with lidocaine (79-87%) for all large joint or bursa injections. It was noted that 36.2% (244/674) of respondents reported using >40mg for at least one injection type. Most (90.5%, 610/674) reported using an anesthetic other than ropivacaine for at least one type of joint or bursa injection. Physicians who reported lidocaine use were less likely to report that their injectate choice was based on literature that they reviewed (OR = 0.41 [0.27-0.62], p <0.001). Respondents predominantly used 5-7mL of total injectate for all large joints or bursae (45-54% of respondents), except for the pes anserine bursa, where 3-4mL was more common (51% of physicians).
Hess, SR et al., 2018 ¹¹	USA	This retrospective cohort trial was approved by the local institutional review board. Following institutional review board's approval, the radiology department provided a comprehensive list of all hip injections between the years of 2000 and 2013.	109	One hundred twenty-nine injection events met the inclusion criteria in a total of 109 patients. From this sample, 23 cases of RDOA were confirmed representing a 21% incidence of RDOA. Twenty-one of the patients (91%) with RDOA had a THA at a median time of 10.2 months (interquartile range: 6.5-11.2) compared with 27 (31%) of those without RDOA at a median time of 24.9 months (interquartile range: 15.3-65.3). Older patients, patients with more severe osteoarthritis, and patients who identified themselves as white were more likely to have a diagnosis of RDOA (P = .008; P = .040; P = .009, respectively).

Paskins, Z et al (2022)⁹ showed an ultrasound guided intra-articular hip injection of corticosteroid and local anaesthetic, administered with advice and education, is a clinically effective treatment for rapid and sustained symptom response compared with advice and education alone for people with hip osteoarthritis.

Cushman, DM et al (2020)¹⁰ showed triamcinolone and methylprednisolone are the most commonly-used corticosteroids, most physicians use 21-40mg of corticosteroid for all injections, and lidocaine is the most-often used local anesthetic. Ropivacaine is used exclusively by less than 10% of physicians; thus, its limited use may have detrimental effects on cartilage and tendons. A third of practitioners appear to be using high-dose corticosteroid injections (>40mg) outside of available evidence base. Injectate volumes are most commonly reported to be 5-7mL for large joints and bursae, with the exception of the pes anserine bursa, which is most commonly 3-4mL. Most providers tend to use the same corticosteroid and anesthetic for all injections.

Hess, SR et al (2018)¹¹ showed 21% incidence of RDOA of the hip in patients receiving intra-articular steroid injections merits several considerations. Patients contemplating intra-articular steroid injections into the hip should be educated about the possibility of RDOA of the hip or progression of preexisting arthritic process, especially those who are elderly

or have higher preinjection KL scores. Finally, given the relatively high progression to THA within 1 year, the cost-effectiveness and safety of this treatment needs scrutiny.

DISCUSSION

Hip osteoarthritis (OA), involving major structural changes of the joint, is one of the most common articular diseases, and the prevalence increases with age. The hip pain and functional disorders in this population result in great troubles in their daily activities and life quality. To reduce pain and restore function, the main therapy methods for hip OA comprise surgical interventions such as total hip replacement (THR) operation and nonsurgical interventions such as exercise therapy and medication therapy. Patients with THR might need a revision of their hip replacement in the future, while nonsurgical interventions before surgery with pain reduction are supposed to delay primary replacement or avoid revision surgery.^{12,13}

The use of hip injection (HI) in the treatment of osteoarthritis (OA) has gained wide popularity. The relatively low cost, fast and simple method of pain relief are amongst its many advantages. Over time, the content of the injection has also evolved from local anesthetic (LA) agents to corticosteroids (CSs), hyaluronic acid (HA) and platelet-rich plasma (PRP). The scope of use of injections in the hip region has grown from traditional aspiration to therapeutic injections. The two main substances used in recent times for pain relief are CSs and HA gel. For decades, low doses of CS were given to surgically unfit patients and to those who are not keen on joint replacement surgery.⁴

Rapid destructive osteoarthritis (RDO) of the hip is a rare syndrome, consisting of rapid joint degeneration and destruction typically involving both the femoral head and acetabulum. It was first described by Forestier in 1957, and its etiology and pathogenesis still remain unclear, but few studies suggest a causal relationship, such as direct toxicity by drugs, subchondral osteonecrosis and ischemia, and immunological mechanisms mediated by cytokines.¹⁴

Intra-articular corticosteroid injections have been widely used and are considered a mainstay in the nonoperative treatment of symptomatic knee osteoarthritis (OA). However, their increased use can have negative implications, including chondral toxicity and a high risk of infections. As a result, nonsteroidal anti-inflammatory drugs have been considered as an alternative.^{15,16}

Two randomised controlled trials showed clinical benefits of corticosteroid and local anaesthetic injection, compared with control injection, at eight weeks after injection, with only one trial reporting outcomes beyond 8 weeks (non-significant reduction in pain between intervention and control). These previous randomised controlled trials compared corticosteroid injection with either local anaesthetic or saline but only one used the comparison of standard care. In addition to uncertainties about patient selection and effectiveness, use of intra-articular corticosteroid injection can also be limited by availability. Hip injections require imaging guidance, either using fluoroscopy or ultrasound, to improve the accuracy of placement.⁹

CONCLUSION

Ultrasound guided intra-articular hip injection of corticosteroid and local anaesthetic, administered with advice and education, is a clinically effective treatment for rapid and sustained symptom response compared with advice and education alone for people with hip osteoarthritis. These findings provide evidence to inform international guidelines and support treatment decision making for policy makers, payers (commissioners), GPs, and clinicians in musculoskeletal services.

REFERENCES

- [1] Abraham PF, Varady NH, Small KM, Shah N, Beltran LS, Kucharik MP, et al. Safety of Intra-articular Hip Corticosteroid Injections: A Matched-Pair Cohort Study. *Orthop J Sport Med.* 2021;9(10):1–7.
- [2] Baker JF, Olave M, Leach W, Doherty CR, Gillcrist RL, White DK, et al. Corticosteroid Injections for Symptomatic Treatment of Osteoarthritis of the Knee: A Pilot Blinded Randomized Trial. *ACR Open Rheumatol.* 2023;5(10):529–35.
- [3] Kose SG, Kose HC, Celikel F, Tulgar S, Akkaya OT. Ultrasound-guided PENG block versus intraarticular corticosteroid injection in hip osteoarthritis: a randomised controlled study. *Korean J Pain.* 2023;36(2):195–207.
- [4] Rampal S, Jaiman A, Tokgöz MA, Arumugam G, Sivananthan S, Singh RSJ, et al. A review of the efficacy of intraarticular hip injection for patients with hip osteoarthritis: To inject or not to inject in hip osteoarthritis? *Jt Dis Relat Surg.* 2022;33(1):255–62.
- [5] Choueiri M, Chevalier X, Eymard F. Intraarticular Corticosteroids for Hip Osteoarthritis: A Review. *Cartilage.* 2021;13(1_suppl):122S-131S.
- [6] Wang Y, Wang K, Qin Y, Wang S, Tan B, Jia L, et al. The effect of corticosteroid injection in the treatment of greater trochanter pain syndrome: a systematic review and meta-analysis of randomized controlled trials. *J Orthop Surg Res [Internet].* 2022;17(1):1–10. Available from: <https://doi.org/10.1186/s13018-022-03175-5>
- [7] Backhouse MR, Halstead J, Roddy E, Dhukaram V, Chapman A, Arnold S, et al. A multi-professional survey of UK practice in the use of intra-articular corticosteroid injection for symptomatic first metatarsophalangeal joint osteoarthritis. *J Foot Ankle Res [Internet].* 2023;16(1):1–8. Available from: <https://doi.org/10.1186/s13047-023->

00672-6

- [8] Streck LE, Braun S, Spilo K, Boettner CS, Brenneis M, Boettner F. How safe are intra-articular corticosteroid injections to the hip? *BMC Musculoskelet Disord*. 2023;24(1):1–8.
- [9] Paskins Z, Bromley K, Lewis M, Hughes G, Hughes E, Hennings S, et al. Clinical effectiveness of one ultrasound guided intra-articular corticosteroid and local anaesthetic injection in addition to advice and education for hip osteoarthritis (HIT trial): single blind, parallel group, three arm, randomised controlled trial. *BMJ*. 2022;377:e068446.
- [10] Cushman DM, Teramoto M, Asay A, Clements ND, McCormick ZL. Corticosteroid and Local Anesthetic Use Trends for Large Joint and Bursa Injections: Results of a Survey of Sports Medicine Physicians. *PM R*. 2021;13(9):962–8.
- [11] Hess SR, O'Connell RS, Bednarz CP, Waligora AC, Golladay GJ, Jiranek WA. Association of rapidly destructive osteoarthritis of the hip with intra-articular steroid injections. *Arthroplast Today* [Internet]. 2018;4(2):205–9. Available from: <https://doi.org/10.1016/j.artd.2017.12.002>
- [12] Zhong HM, Zhao GF, Lin T, Zhang XX, Li XY, Lin JF, et al. Intra-Articular Steroid Injection for Patients with Hip Osteoarthritis: A Systematic Review and Meta-Analysis. *Biomed Res Int*. 2020;2020.
- [13] Buyuk AF, Kilinc E, Camurcu IY, Camur S, Ucpunar H, Kara A. Compared efficacy of intra-articular injection of methylprednisolone and triamcinolone. *Acta Ortop Bras*. 2017;25(5):206–8.
- [14] Tiwari A, Karkhur Y, Keeney JA, Aggarwal A. Rapid destructive osteoarthritis of the hip after intra-articular steroid injection. *Arthroplast Today* [Internet]. 2018;4(2):184–6. Available from: <https://doi.org/10.1016/j.artd.2018.01.002>
- [15] Xu J, Qu Y, Li H, Zhu A, Jiang T, Chong Z, et al. Effect of Intra-articular Ketorolac Versus Corticosteroid Injection for Knee Osteoarthritis: A Retrospective Comparative Study. *Orthop J Sport Med*. 2020;8(4):1–5.
- [16] Estee MM, Cicuttini FM, Page MJ, Butala AD, Wluka AE, Hussain SM, et al. Efficacy of corticosteroids for hand osteoarthritis - a systematic review and meta-analysis of randomized controlled trials. *BMC Musculoskelet Disord* [Internet]. 2022;23(1):1–15. Available from: <https://doi.org/10.1186/s12891-022-05619-9>