

COMPUTED-ASSISTED DIAGNOSIS IN DIAGNOSTIC CERVICAL CANCER IMAGING : A TEN YEARS SYSTEMATIC REVIEW

^{1*}Rahmita Kusuma Dewi, ²Asri Kurnia Dewi, ³Nandya Meitadani

^{1*}Faculty of Medicine, General Achmad Yani University, Bandung, Indonesia

²Hermina Arcamanik General Hospital, Bandung, Indonesia

³Ny. R.A. Habibie Kidney Special Hospital, Bandung, Indonesia

Correspondence Author:
rahmitakesuma@gmail.com

ABSTRAK

Background: Cervical cancer is one of the most common malignant tumors in the world, and it is the fourth leading cause of cancer in women. The morbidity and mortality of cervical cancer in the developing countries are distinctly higher than those in the developed countries. Computer-assisted diagnosis is key for scaling up cervical cancer screening, but current algorithms perform poorly on whole slide image analysis and generalization.

The aim: This study aims to show about computed-assisted diagnosis in diagnostic cervical cancer imaging.

Methods: By comparing itself to the standards set by the Preferred Reporting Items for Systematic Review and Meta-Analysis (PRISMA) 2020, this study was able to show that it met all of the requirements. So, the experts were able to make sure that the study was as up-to-date as it was possible to be. For this search approach, publications that came out between 2014 and 2024 were taken into account. Several different online reference sources, like Pubmed and SagePub, were used to do this. It was decided not to take into account review pieces, works that had already been published, or works that were only half done.

Result: In the PubMed database, the results of our search brought up 153 articles, whereas the results of our search on SagePub brought up 180 articles. The results of the search conducted for the last year of 2014 yielded a total 53 articles for PubMed and 72 articles for SagePub. The result from title screening, a total 18 articles for PubMed and 27 articles for SagePub. In the end, we compiled a total of 10 papers. We included five research that met the criteria.

Conclusion: Computed-assisted medical diagnosis can successfully complete a variety of medical tasks by efficiently exploring the essence of a large amount of clinical data. The colposcopy-guided cervical biopsy is essential for detecting CIN in cervical cancer screening, but there are difficulties with increasing sensitivity globally.

Keyword: Computed-assisted, diagnostic, imaging, cervical cancer.

INTRODUCTION

Cervical cancer is a malignant tumor with high incidence among gynecological diseases. It is one of the four most common cancers and poses a serious threat to women's life and health. Epidemiological investigations have found that cervical cancer and its carcinoma in situ are closely related to factors such as sexually transmitted diseases, smoking, and premature sex (<16 years old). In addition, the diseased population is becoming younger and younger. Generally, cervical cancer has no significant feature in the early stage and occasionally manifests as increased vaginal discharge. The clinical methods for early cervical cancer diagnosis are the three examinations of colposcopy, cervical cytology, and cervical biopsy. However, biopsy is invasive and tissue sampling determines its accuracy. Early lesions in tumor tissues are not easy to find and occasionally appear as punctate lesions, which may lead to missed diagnosis. Therefore, an accurate and less traumatic diagnostic method is needed. The accuracy of early diagnosis and clinical staging of cervical cancer is of great significance for improving the prognosis and survival rate of cervical cancer patients, and overestimating or underestimating the severity of cancer tissue lesions will make an adverse effect on the prognosis.^{1,2}

The emergence of AI in the 21st century has shown great promise to perform such crucial but tedious tasks both thoroughly and tirelessly. AI has changed our daily lives in various ways, and its applications in medical diagnosis has increased rapidly. The field of AI has been well developed, including reinforcement learning, supervised learning and unsupervised learning, such as machine learning (ML), pattern recognition, convolutional neural networks (CNNs), feedback neural networks, self-supervised learning, and weakly supervised learning, etc. Today, these technologies have an increasingly important role in biomedical and clinical application. Different AI systems have been developed to address the needs in clinical diagnosis, for example cardiac systolic dysfunction screening and skin cancer classification which achieved diagnostic results that are comparable to the level of clinical experts.³

Deep learning and artificial intelligence in general have positively affected computer-assisted medical diagnosis, especially with the availability of large quantities of clinical data that can help artificial intelligence models to achieve remarkable performance on various medical tasks. Research has indicated that medical artificial intelligence (AI) and computer-assisted diagnosis (CAD) may aid in the detection of cervical lesions and enhance diagnostic accuracy through the use of deep learning and medical image processing technology, combined with possible physiological and pathological knowledge. Investigations in the areas of optical coherence tomography, radiology, computerized tomography scan, colonoscopy, and pathologic slides have suggested that computer algorithms, trained on a large number of medical images in a convolutional neural network (CNN), may approach or even exceed the diagnostic accuracy of clinicians.^{4,5}

METHODS

Protocol

By following the rules provided by Preferred Reporting Items for Systematic Review and Meta-Analysis (PRISMA) 2020, the author of this study made certain that it was up to par with the requirements. This is done to ensure that the conclusions drawn from the inquiry are accurate.

Criteria for Eligibility

For the purpose of this literature review, we compare and contrast computed-assisted diagnosis in diagnostic cervical cancer imaging. It is possible to accomplish this by researching or investigating computed-assisted diagnosis in diagnostic cervical cancer imaging. As the primary purpose of this piece of writing, demonstrating the relevance of the difficulties that have been identified will take place throughout its entirety.

In order for researchers to take part in the study, it was necessary for them to fulfil the following requirements: 1) The paper needs to be written in English, and it needs to determine about computed-assisted diagnosis in diagnostic cervical cancer imaging. In order for the manuscript to be considered for publication, it needs to meet both of these requirements. 2) The studied papers include several that were published after 2014, but before the time period that this systematic review deems to be relevant. Examples of studies that are not permitted include editorials, submissions that do not have a DOI, review articles that have already been published, and entries that are essentially identical to journal papers that have already been published.

Search Strategy

We used " computed-assisted diagnosis in diagnostic cervical cancer imaging." as keywords. The search for studies to be included in the systematic review was carried out using the PubMed and SagePub databases by inputting the words: ("Cervical cancer"[MeSH Subheading] OR "diagnostic of cervical cancer"[All Fields] OR "Cervical cancer imaging"[All Fields]) AND ("Computed-assisted diagnostic"[All Fields] OR "Computes assisted cervical cancer imaging "[All Fields]) AND ("Imaging of cervical cancer"[All Fields]) OR ("Computed-assisted diagnosis of cervical cancer" [All Fields])) used in searching the literature.

Data retrieval

After reading the abstract and the title of each study, the writers performed an examination to determine whether or not the study satisfied the inclusion criteria. The writers then decided which previous research they wanted to utilise as sources for their article and selected those studies. After looking at a number of different research, which all seemed to point to

the same trend, this conclusion was drawn. All submissions need to be written in English and can't have been seen anywhere else.

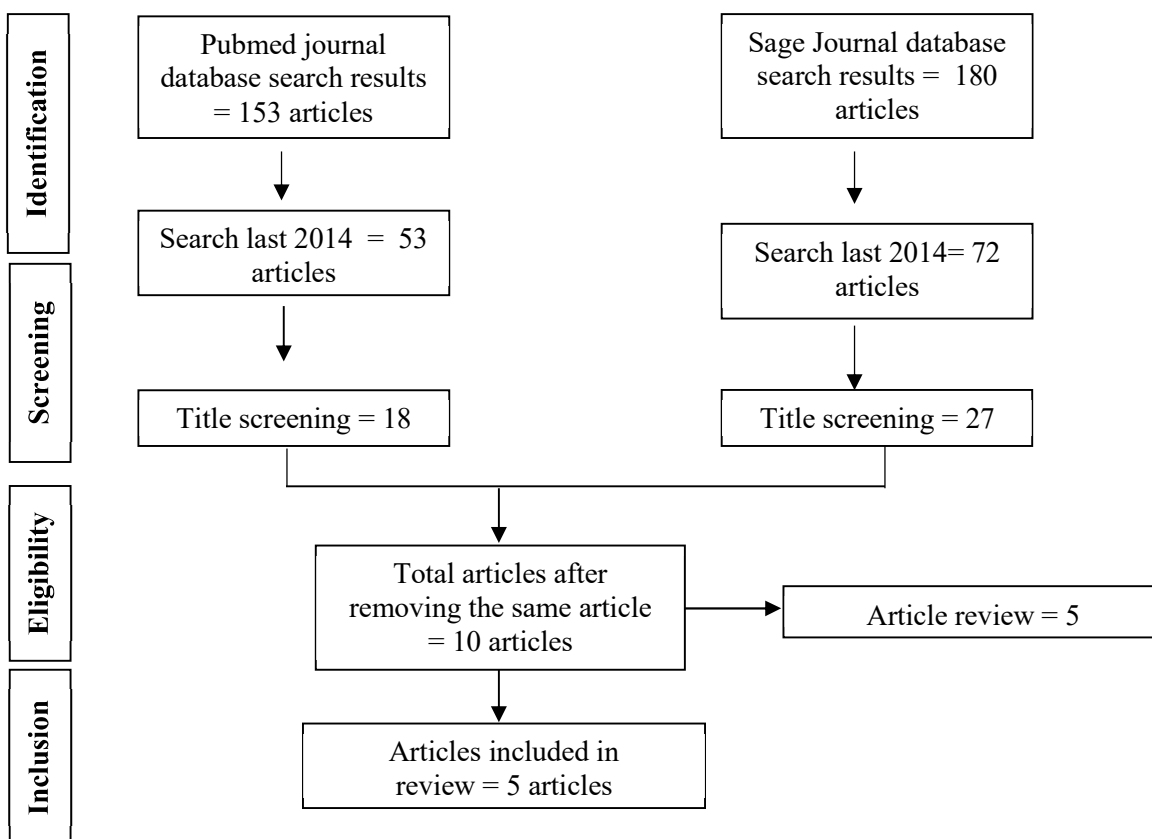


Figure 1. Article search flowchart

Only those papers that were able to satisfy all of the inclusion criteria were taken into consideration for the systematic review. This reduces the number of results to only those that are pertinent to the search. We do not take into consideration the conclusions of any study that does not satisfy our requirements. After this, the findings of the research will be analysed in great detail. The following pieces of information were uncovered as a result of the inquiry that was carried out for the purpose of this study: names, authors, publication dates, location, study activities, and parameters.

Quality Assessment and Data Synthesis

Each author did their own study on the research that was included in the publication's title and abstract before making a decision about which publications to explore further. The next step will be to evaluate all of the articles that are suitable for inclusion in the review because they match the criteria set forth for that purpose in the review. After that, we'll determine which articles to include in the review depending on the findings that we've uncovered. This criteria is utilised in the process of selecting papers for further assessment. In order to simplify the process as much as feasible when selecting papers to evaluate. Which earlier investigations were carried out, and what elements of those studies made it appropriate to include them in the review, are being discussed here.

RESULT

In the PubMed database, the results of our search brought up 153 articles, whereas the results of our search on SagePub brought up 180 articles. The results of the search conducted for the last year of 2014 yielded a total 53 articles for PubMed and 72 articles for SagePub. The result from title screening, a total 18 articles for PubMed and 27 articles for SagePub. In the end, we compiled a total of 10 papers. We included five research that met the criteria.

Tan, X *et al* (2021)⁶ showed The CNN-based TCT cervical cancer cell classification system proposed in this paper can effectively exclude negative smear samples, and identify the suspicious population in cervical cancer screening. It also showed high sensitivity and excellent performance in the identification of cervical cancer screening, which can save time for pathologists and provide an excellent secondary prevention effect. In comparison to the conventional diagnostic

methods, this system has good robustness, objectivity, and small computational cost. Meanwhile, our system provides a possibility for online diagnosis of TCT images and is expected to contribute to the construction of primary medical care.

Gaona, YJ *et al* (2022)⁷ showed that synthetic images improve the colposcopy diagnosis performance of our AI tool for the classification of cervix images. We propose a combined Deep Learning method (Unet) plus Machine Learning (SVM) to obtain the best index of identification, classification, and prediction of cervix abnormalities through the processing of images. However, the problem of limited data in this project motivated us to apply methods for synthetic data augmentation in order to enlarge the colposcopy dataset.

Table 1. The literature include in this study

Author	Origin	Method	Sample Size	Result
Tan, X <i>et al.</i> , 2021 ⁶	China	A retrospective, multicohort, multicenter study	290	The sensitivity and specificity of the proposed cervical cancer screening system was 99.4 and 34.8%, respectively, with an area under the curve (AUC) of 0.67. The model could also distinguish between negative and positive cells. The sensitivity values of the atypical squamous cells of undetermined significance (ASCUS), the low-grade squamous intraepithelial lesion (LSIL), and the high-grade squamous intraepithelial lesions (HSIL) were 89.3, 71.5, and 73.9%, respectively. This system could quickly classify the images and generate a test report in about 3 minutes. Hence, the system can reduce the burden on the pathologists and saves them valuable time to analyze more complex cases.
Gaona, YJ <i>et al.</i> , 2022 ⁷	Ecuador	Two sets of images were used: the Intel & Mobile ODT Cervical Cancer Screening public dataset, and a private dataset from a public hospital in Ecuador during a routine colposcopy, after the application of acetic acid and lugol.	460	The CAD system was evaluated for the ability to predict the risk of cervical cancer. The lesion segmentation metric results indicate a DICE of 50%, a precision of 65%, and an accuracy of 80%. The classification results' sensitivity, specificity, and accuracy were 70%, 48.8%, and 58%, respectively. Randomly, 20 images were selected and sent to 13 expert colposcopists for a statistical comparison between visual evaluation experts and the CAD tool (<i>p</i> -value of 0.597).
Liu, L <i>et al.</i> , 2021 ⁸	China	The residual neural network (ResNet) probability was calculated for each patient to reflect the probability of lesions through	7530	The model that combines ResNet and clinical features performs better than ResNet alone. In the classification of NC and LSIL+, the area under the receiver operating characteristic curve (AUC), accuracy, sensitivity, specificity, positive predictive

		a ResNet model.		value (PPV) and negative predictive value (NPV) were 0.953, 0.886, 0.932, 0.846, 0.838, and 0.936, respectively. In the classification of HSIL- and HSIL+, the AUC, accuracy, sensitivity, specificity, PPV, and NPV were 0.900, 0.807, 0.823, 0.800, 0.618, and 0.920, respectively. In the two classification tasks, the diagnostic performance of the model was determined to be comparable to that of the senior colposcopist and exhibited a stronger diagnostic performance than the junior colposcopist.
Cheng, S et al., 2021⁹	China	The slide acquisition is performed in accordance with the guidelines of the Medical Ethics Committee of Tongji Medical College at Huazhong University of Science and Technology.	3545	On multi-center independent test sets of 1,170 patient-wise WSIs, we achieve 93.5% <i>Specificity</i> and 95.1% <i>Sensitivity</i> for classifying slides, comparing favourably to the average performance of three independent cytopathologists, and obtain 88.5% true positive rate for highlighting the top 10 lesion cells on 447 positive slides. After deployment, our system recognizes a one gigapixel WSI in about 1.5 min. For the areas with a probability higher than 0.5 predicted by the LR model, we perform some morphological operations on the corresponding location heatmap to generate the location mask. A cropped image tile of 256×256 ($0.243 \mu\text{m}/\text{pixel}$) according to the location mask is input to the HR model and a new lesion probability is obtained. Finally, all identified lesion cells in WSIs are sorted by lesion probabilities, and the top 10 typical lesion cells are recommended for cytopathologist reviewing. Further, the RNN model integrates the CNN image features of the recommended top 10 lesion cells to classify WSIs. For each lesion cell tile, 2,048-dimensional features are extracted by the HR model. Then the total $10 \times 2,048$ -dimensional features are input to the RNN model, and

				positive probabilities of WSIs are output.
Shamsunder, S <i>et al.</i> , 2023 ¹⁰	India	A prospective observational, single-arm, non-randomized study	927	Histopathology was considered a gold standard. Data on 877 SS-AI, 485 colposcopy, and 213 histopathology were available for analysis. The SS-AI showed high sensitivity (90.3%), specificity (75.3%), accuracy (84.04%), and correlation coefficient (0.670, $p = 0.0$) in comparison with histology at the CINI+ cutoff. In conclusion, the AI-enabled Smart Scope [®] test is a good alternative to the existing screening tests as it gives a real-time accurate assessment of cervical health and an opportunity for immediate triaging with visual evidence.

Liu, L *et al* (2021)⁸ showed a deep learning-based CAD system that combined colposcopy images and clinical features for colposcopy image classification. The proposed CAD system shows performance comparable to that of the senior colposcopist in colposcopy image classification. The CAD system can provide an objective diagnostic basis for colposcopists and has potential clinical application value. In the future, we will collect multicenter data and conduct more extensive research to apply this CAD model to clinical practice.

Cheng, S *et al* (2021)⁹ showed that will focus on research about AI-enhanced portable microscopy and augmented reality microscopy to further expand our system. At present, professional but expensive scanners are still required, preventing the spread of cervical cancer screening in remote and underdeveloped areas. Thus, developing portable microscope-based cervical cancer computer-aided diagnosis is necessary. In addition, developing real-time augmented reality microscopes can provide friendly human-computer interaction for AI-assisted slide screening without changing the conventional working mode of cytopathologists.

Shamsunder, S *et al* (2023)¹⁰ showed The AI-enabled Smart Scope[®] test is an accurate digital VIA test that classifies cervical health in multiclass categories. It can be used as a point-of-care screening test as its sensitivity is 90.3%. This test can also be implemented as a point-of-care triaging test as its PPV is 83.58%. The accuracy of the AI-enabled Smart Scope[®] test is 84.04% compared to that of colposcopy (59.15%). Since it is AI-enabled, the results are not subjective in nature. The Smart Scope[®] test is user-friendly, can be performed by a minimally trained nurse, and based on the auto-assessment, it is possible to take an immediate decision regarding patient management in a minimalistic setting such as PHCs in LMICs.

DISCUSSION

The cervix is part of the female reproductive organ structurally found at the lower fibromuscular portion of the uterus. It contains two kinds of cells: rectangular columnar cells and flat scale-like squamous cells. Abnormal cells are developed in the transformation zone, which is an area where columnar cells are constantly changing into squamous cells. The location of the transformation zone varies among women. Based on transformation zone location, cervix is classified as cervix type 1, type 2, and type 3. The cells in the transformation zone develop gradually to abnormal cells and could change into cervical cancer through time.^{11,12}

Cervical cancer is one of the leading causes of cancer-related deaths in women, worldwide, with 80% of the cases occurring in developing countries. According to the human papillomavirus (HPV) information center report, about 6294 new cervical cancer cases are diagnosed annually in Ethiopia. In remote areas, which have poor medical conditions with insufficient healthcare accessibility and unqualified medical staff, cervical cancer incidence and mortality are estimated to be higher.¹¹

Based on artificial intelligence and deep learning, computer assisted medical diagnosis can efficiently and scientifically deal with a large quantity of clinical data and achieve comparable performance on various medical tasks. Studies have suggested that medical artificial intelligence and computer assisted diagnosis can help detect lesions and improve diagnosis accuracy by using deep learning and medical image processing technology plus some possible physiological and pathological knowledge. Studies in optical coherence tomography, radiology, computerized tomography scan,

colonoscopy and pathologic slides have indicated that computer algorithms can approach and even surpass the diagnostic accuracy of clinicians after training a large number of medical images in a convolutional neural network (CNN).^{13,14}

There are several techniques for computer-aided diagnosis of cervical cancer. Most of them use cytological images. However, an increasing number of studies are developing methods for automatic classification of images captured during VIA, and often, adding images taken during the visual inspection with Lugol's iodine (VILI) or with the green lens. Particularly, the authors of apply convolutional neural networks (CNN) to images captured with colposcopes.¹⁵

Nevertheless, standard colposcopes are rarely available for screening in low-income countries due to limited financial resources, health manpower, and facilities. Consequently, recent studies are using other acquisition devices. For instance, a low-cost and portable colposcope has been developed and used to acquire images during VIA and VILI. From these images, textural-based features are extracted and used in a support vector machine model. Another example is a colposcope based on a smartphone with optical lenses attached that incorporates an Artificial Intelligence (AI) classifier. The smartphone-based system was evaluated in, after highly selecting the images and using gynecologic oncologists' impressions as a reference standard, showing a large variable diagnosis among experts and demonstrating the potential of smartphones as an aiding tool for VIA.¹⁵

CONCLUSION

Computed-assisted medical diagnosis can successfully complete a variety of medical tasks by efficiently exploring the essence of a large amount of clinical data. The colposcopy-guided cervical biopsy is essential for detecting CIN in cervical cancer screening, but there are difficulties with increasing sensitivity globally.

REFERENCES

- [1] Zhang Z, Zhang C, Xiao L, Zhang S. Diagnosis of Early Cervical Cancer with a Multimodal Magnetic Resonance Image under the Artificial Intelligence Algorithm. *Contrast Media Mol Imaging*. 2022;2022.
- [2] Prochaska J, Benowitz N. 乳鼠心肌提取 HHS Public Access. *Physiol Behav*. 2016;176(1):100–106.
- [3] Zhu X, Li X, Ong K, Zhang W, Li W, Li L, et al. Hybrid AI-assistive diagnostic model permits rapid TBS classification of cervical liquid-based thin-layer cell smears. *Nat Commun*. 2021;12(1):1–12.
- [4] Darwish M, Altabel MZ, Abiyev RH. Enhancing Cervical Pre-Cancerous Classification Using Advanced Vision Transformer. *Diagnostics*. 2023;13(18).
- [5] Ma JH, You SF, Xue J Sen, Li XL, Chen YY, Hu Y, et al. Computer-aided diagnosis of cervical dysplasia using colposcopic images. *Front Oncol*. 2022;12(August):1–11.
- [6] Tan X, Li K, Zhang J, Wang W, Wu B, Wu J, et al. Automatic model for cervical cancer screening based on convolutional neural network: a retrospective, multicohort, multicenter study. *Cancer Cell Int [Internet]*. 2021;21(1):1–10. Available from: <https://doi.org/10.1186/s12935-020-01742-6>
- [7] Jiménez Gaona Y, Castillo Malla D, Vega Crespo B, Vicuña MJ, Neira VA, Dávila S, et al. Radiomics Diagnostic Tool Based on Deep Learning for Colposcopy Image Classification. *Diagnostics*. 2022;12(7).
- [8] Liu L, Wang Y, Liu X, Han S, Jia L, Meng L, et al. Computer-aided diagnostic system based on deep learning for classifying colposcopy images. *Ann Transl Med*. 2021;9(13):1045–1045.
- [9] Cheng S, Liu S, Yu J, Rao G, Xiao Y, Han W, et al. Robust whole slide image analysis for cervical cancer screening using deep learning. *Nat Commun*. 2021;12(1):1–10.
- [10] Shamsunder S, Mishra A, Kumar A, Kolte S. Automated Assessment of Digital Images of Uterine Cervix Captured Using Transvaginal Device—A Pilot Study. *Diagnostics*. 2023;13(19):1–10.
- [11] Habtemariam LW, Zewde ET, Simegn GL. Cervix Type and Cervical Cancer Classification System Using Deep Learning Techniques. *Med Devices Evid Res*. 2022;15(June):163–76.
- [12] Jusman Y, Ng SC, Abu Osman NA. Intelligent screening systems for cervical cancer. *Sci World J*. 2014;2014.
- [13] Yuan C, Yao Y, Cheng B, Cheng Y, Li Y, Li Y, et al. The application of deep learning based diagnostic system to cervical squamous intraepithelial lesions recognition in colposcopy images. *Sci Rep [Internet]*. 2020;10(1):1–12. Available from: <https://doi.org/10.1038/s41598-020-68252-3>
- [14] Taddese AA, Tilahun BC, Awoke T, Atnaflu A, Mamuye A, Mengiste SA. Deep-learning models for image-based gynecological cancer diagnosis: a systematic review and meta-analysis. *Front Oncol*. 2023;13(January):1–17.
- [15] Viñals R, Vassilakos P, Rad MS, Undurraga M, Petignat P, Thiran JP. Using dynamic features for automatic cervical precancer detection. *Diagnostics*. 2021;11(4).