

MASSIVE PRIMARY LEIOMYOSARCOMA ON CAVUM THORAX : A VERY RARE CASE

^{1,2*}Fulgensius Atin, ²R. Dhany Prasetyanto, ²Puruhito, ¹Alyssa Claudia Valerie Gunawan, ²Monica Goenawan

¹Faculty of Medicine, Widya Mandala Catholic University, Surabaya, Indonesia

²St. Vincentius A Paulo Catholic Hospital, Surabaya, Indonesia

Corresponding Author:

fulgensiusatin@gmail.com

ABSTRACT

The cavum thorax primary leiomyosarcoma is extremely rare and unusual case. leiomyosarcoma as smooth muscle carcinoma could be comes from various part of body as primary site, but in the case of cavum thorax leiomyosarcoma its estimated only 1-4% of all soft tissue sarcoma. In this report we present a 69 years old woman came to the outpatient clinic with a big lump in the chest. This lump has been felt for 1 year and was a big and bizarre looking tumor, pain was felt in the right chest with intensity of 4-5 visual analog scale. Difficulty to breath and shortness of breath was not complained by the patient, nausea and vomiting was not complained. The patient has a history of uterine tumor that has been done by surgery. Diagnostic test of Multidetector Computed Tomography (MDCT) scan and ultrasonography has been done in this patient, and show a suggestive malignant soft tissue tumor. The surgery has been done with preoperative internal mammary artery embolization to prevent massive bleeding. A 15 cm length, 9 cm wide and 500 grams of weight tumor was evacuated. The immunohistochemistry examination was performed to the tumor specimen, and the result was a leiomyosarcoma tissue. A good examination, early detection with adequate diagnostic tools and adequate surgery as the only option of treatment is a predicting factor of successful treatment, due to lack of treatment option and ineffectiveness use of adjuvant therapy.

Keyword : Metastasis, Uterine leiomyosarcoma, surgery

INTRODUCTION

Leiomyosarcoma is a smooth muscle malignant tumor. This tumor approximately 25% from all of adult soft tissue sarcoma. Leiomyosarcoma mostly affected women more than men, its approximate 2,15 : 1 ratio between women and men. This tumor comes from various part of body from pulmonary to testicles, but this tumor commonly found in uterine and called as uterine leiomyosarcoma. ¹⁻³. The primary cavum thorax leiomyosarcoma was extremely rare case and estimated only 1-4 % of all soft tissue carcinoma case^{4,5}. Leiomyosarcoma belong to the group of soft tissue sarcoma with complex and unbalanced karyotypes which result in severe genomic instability. The cytogenetic and molecular changes in LMS are not consistent, which makes it a very heterogeneous disease. Some of the most common changes in LMS occur in the form of loss in chromosomes 10q(PTEN) and 13q (RB1) and gain at 17p (TP53) ^{6,7}. Leiomyosarcoma metastasis of cavum thorax was a rare condition, and difficulties on treatment make this metastasis become such a challenging case. Surgery is the only option for treatment the leiomyosarcoma, due to there is no evidence of benefit using neoadjuvant or adjuvant therapy, and despite of adequate local treatment the rate of local recurrency and metastasis is still high an approximately 40%^{3,8,9}.

Surgery as the first line treatment option still becomes a challenge for surgeons due to anatomical and structural particularities that require a high knowledge and technique. The surgery also has risk of complication to thoracic cavity failure and leading to respiratory failur¹⁰. Highly rate of metastasis and limited option of therapy made a low survival rate in leiomyosarcoma. Despite adequate surgery, the rate of survival metastatic leiomyosarcoma patient undergoing metastasectomy in five-years 31% (95% CI 18-44%) and median overall survival 59,6 months (95% CI 33,3-66%)³.

Case Report

A 69 year old woman came to the outpatient clinic with a big lump in the chest. This lump has been felt since 1 year ago. The lump was a big and bizarre looking tumor, pain was felt in the right chest by the patient with intensity of 4-5 visual analog scale. Difficulty to breath and shortness of breath was not complained by the patient, nausea and vomiting was not complained. The patient has a history of uterine tumor that has been done by surgery and there is no adjuvant therapy following the surgery, the type of uterine tumor was not known by the patient. A physical examination has been done, there is no evidence of elevated jugular vein, sign of superior vena cava syndrome and ascites was not found. The patient was alert with blood pressure 120/80 mmHg, heart rate 80 times per minute, respiratory rate 18 times per minute, temperature 36,2°C, and peripheral oxygen saturation 98%. The lump was found in the midline to the right part of the thorax with hard consistency, immobile, uneven surface, and 9 x 8 x 7,8 cm in size. Laboratory examination has been done with hemostatic profile, renal function, electrolyte, liver function, and infection screening test for surgery (**table 1**).

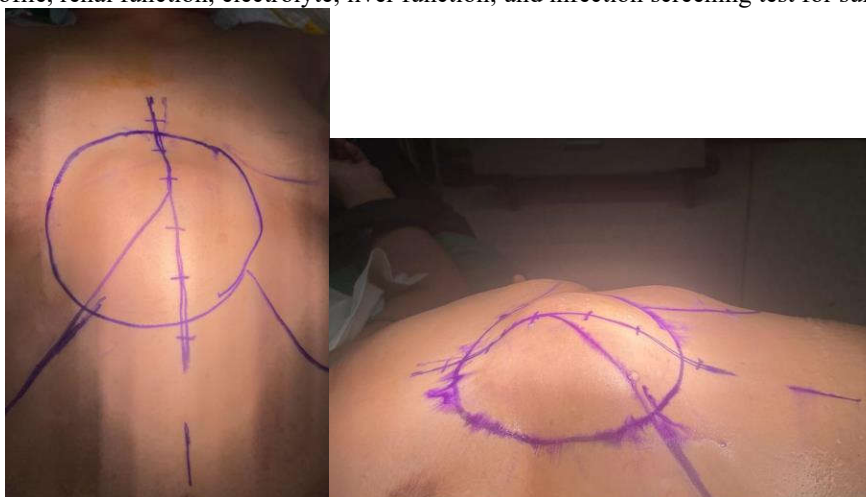


Image 1. Clinical appearance of tumor before surgery

Laboratory examination	Result
Hemostatic profile	
Hb	12,8g/dL;
Leucocyte	5080/mm3
Thrombocyte	265000/mm3
Hematocrit	40%
Bleeding Time	1 minute 15 second
Clothing Time	7 minute 58 second

PT	14,9 second
APTT	30,2 second
Renal Function	
BUN	12,6 mg/dL
Creatinin	0,56 mg/dL
eGFR	114 mL/min/1,73
Electrolyte	
Sodium	141 mmol/L
Potassium	4,18 mmol/L
Liver function	
Albumin	3,5 g/dL
SGOT	20,1 U/L
SGPT	11,4 U/L
Infection screening	
HIV	negative
HBsAg	negative

Table 1. laboratory examination result

Radiology examination was done including chest X-Ray, Multidetector Computed Tomography (MDCT) scan, and thoracic ultrasonography. X-Ray examination does not show any sign of pneumonia or pulmonary nodule, but show a cardiomegaly, and dextroscoliosis thorax. The MDCT scan shows that there is a suggestive malignant tissue in the thoracoabdominal region predominantly in the right paramedian, the size of tumor was 11,28 x 9,55 x 10,7 cm and infiltrate the right abdominal rectus. The tumor has expand to lower anterior mediastinum and pressing the right ventricle but limited by the fat plane. In the abdominal area, the tumor presses the right lobe of the liver, and infiltrates the right anterior diaphragm. The tumor was hypervascularized and fed by a branch of the mesenteric artery. The sixth and seventh costae and xyphoid process was surrounded by the mass. The ultrasonography examination showed a hyper vascular soft tissue with irregular margin and heterogeneous soft tissue in abdominal wall epigastric region with unclear origin suggestive to a soft tissue tumor, and there is no connection to intra abdomen and mammae.

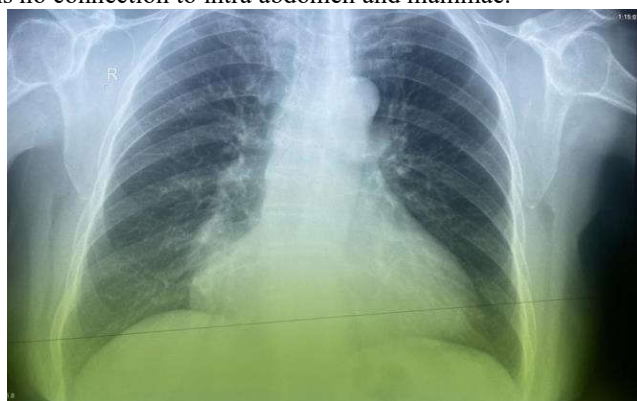


Image 2. Thoracic X-Ray

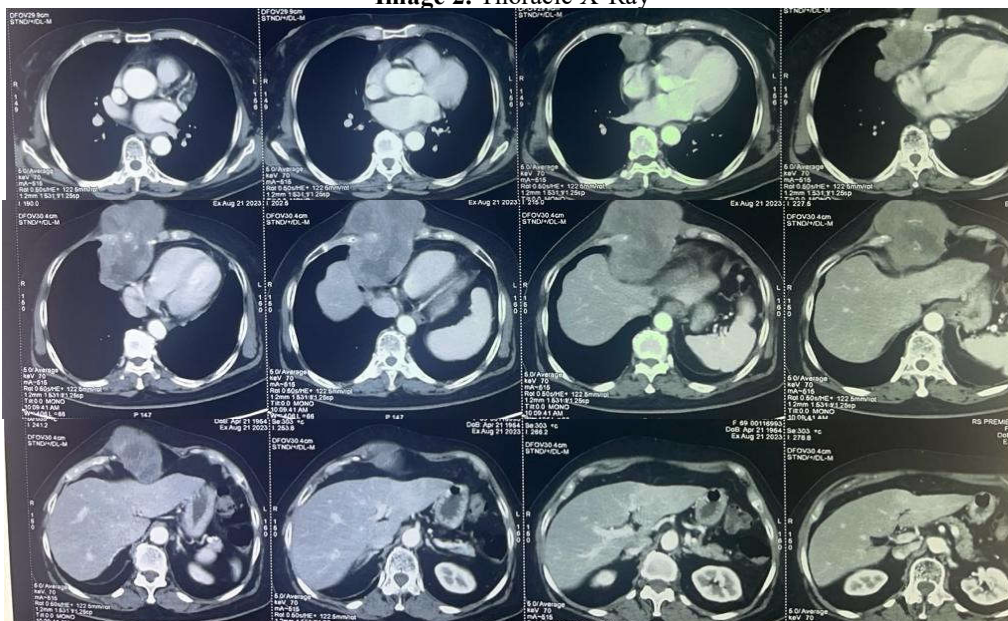


Image 3. Thoracoabdominal Computed Tomography

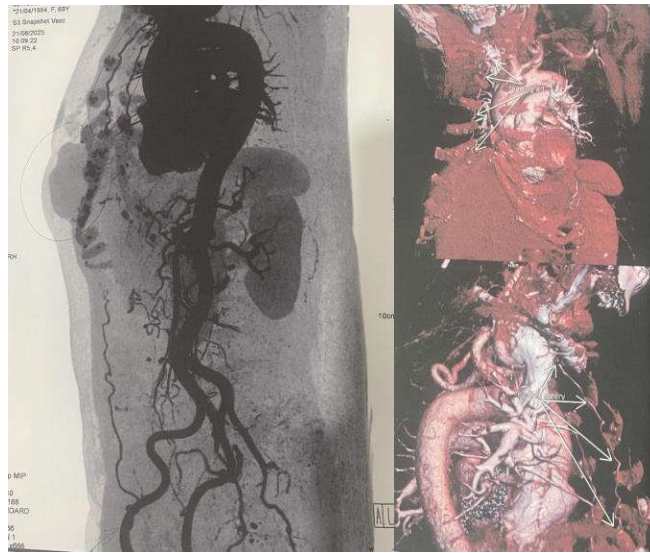


Image 4. Angiography view with bone masking

The tumor was evacuated by surgery after embolization of the internal mammary artery as the tumor feeding artery before. The evacuated tumor size is 15 cm length, 9 cm wide and 500 grams of weight. The surgery was done by sternotomy procedure, and the tumor was not attached to the diaphragm but attached to the arcus costae and xiphoid process. During the surgery there is 500 cc blood loss and there is no change in patient hemodynamic. Then the tumor was evacuated and the surgery area was closed by a flap from abdominal muscle that was done by a plastic surgeon. After surgery the tumor specimen was sent to pathologic to perform immunohistochemistry examination with Desmin antibody, SMA, S100, Ki67, and CD 34 immunohistochemistry staining, the result is leiomyosarcoma tumor (**table 2**). After that patient was prepared to be refer to another hospital for future radiotherapy and chemotherapy treatment.

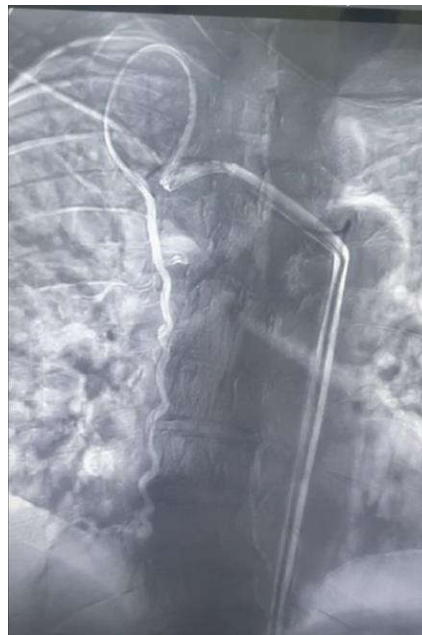

Image 5. Embolization of internal mammary artery

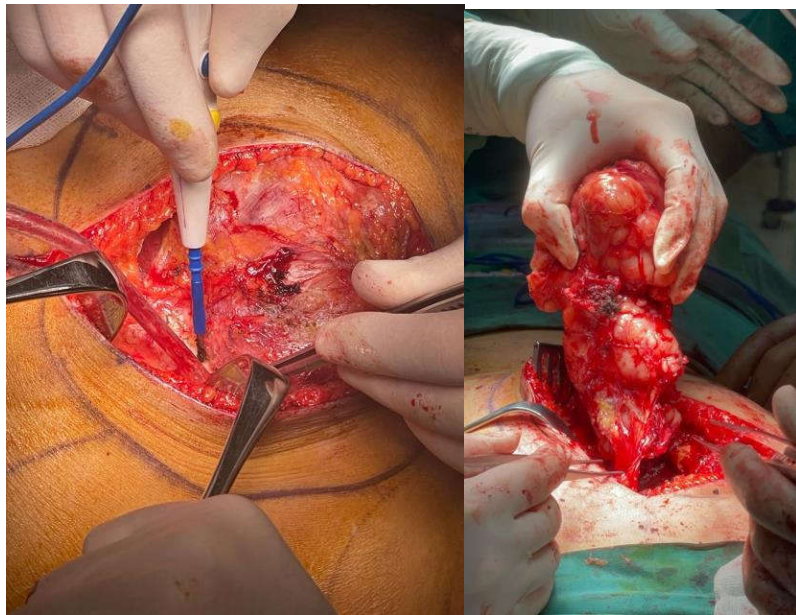


Image 6. The evacuation of tumor was done by partial lower sternotomy extended to right anterior thoracotomy

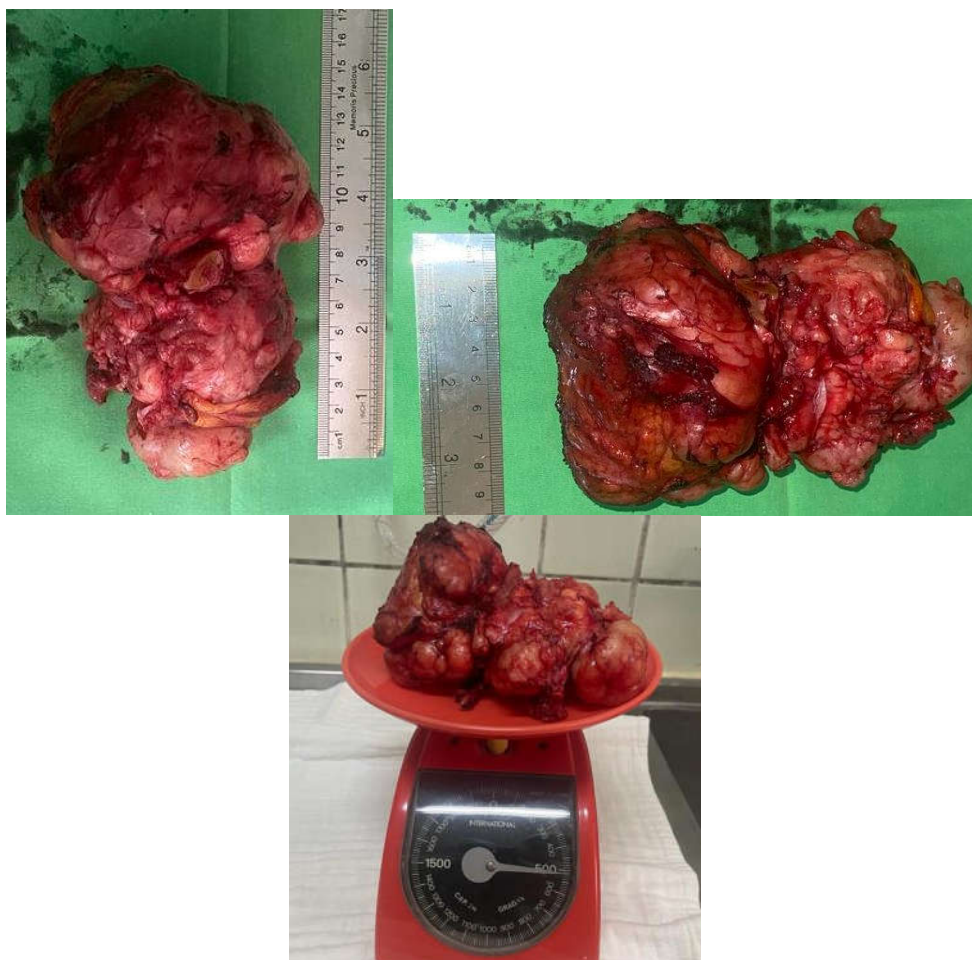

Image 7. The tumor size after surgery

Immunohistochemistry staining	Result
Desmin	Positive in cell cytoplasm
SMA	Positive in cell cytoplasm
S100	Negative in cell cytoplasm and nuclei
CD34	Negative in cell membrane
Ki67	Proliferation index 30%

Conclusion : Appropriate with leiomyosarcoma tissue

Table 2. Immunohistochemistry test result

Discussion

Leiomyosarcoma are rare malignant mesenchymal tumors, but the most common type of soft tissue sarcoma (STS) in adults and account for 25% of all soft tissue tumors. The tumor is composed of malignant mesenchymal cells that show distinct features of smooth muscle lineage. Leiomyosarcoma mostly affects women more than men with an approximate 2,15: 1 ratio. Leiomyosarcoma arises from a variety of primary anatomic sites but commonly comes from the uterus. In pathological findings, leiomyosarcoma is usually a solitary and large tumor (>5 cm) in $\geq 75\%$ cases¹⁻³. In the case of primary leiomyosarcoma in the chest wall is extremely rare and unusual, an estimated only 1-4% of all soft tissue sarcoma case^{4,5}. Age has become one of factors to develop leiomyosarcoma, it has been reported that incidence of leiomyosarcoma increases as age increases, and the younger age at diagnosis is important since younger patients exhibited better survival statistic¹. In this case despite there is an uterine tumor history in this patient, the cavum thorax leiomyosarcoma is suggested to be an a primary tumor due to there is no evidence of uterine leiomyosarcoma before.

Leiomyosarcoma belongs to the group of soft tissue sarcomas with complex and unbalanced karyotypes which result in severe genomic instability. The cytogenetic and molecular changes in LMS are not consistent, which makes it a very heterogeneous disease. Some of the most common changes in LMS occur in the form of loss in chromosomes 10q (PTEN) and 13q (RB1) and gain at 17p (TP53). A few noteworthy points to be noted here are loss of 13q results in mutation in the RB1 gene (retinoblastoma gene), which is a tumor suppressor gene identified in 90% of patients with leiomyosarcoma. A lower rate of p53 is observable in LMS compared to other STS. A higher rate of amplification of MDM2 is present in patients with LMS. The deletion of chromosome 10q leads to a mutation in the PTEN tumor suppressor gene, which leads to the activation of the phosphatidylinositol 3-kinase (PI3K)/ (protein kinase B) AKT pathway. Profiling studies have identified new targets, such as Aurora-A and Aurora-B kinases, which are consistently overexpressed in uterine LMS and can be therapeutic targets in the future^{6,7}.

Cavum thorax leiomyosarcoma can result in non-specific symptoms. Commonly this type of leiomyosarcoma symptom was coughing, chest pain and shortness of breath, or could be asymptomatic⁴. As in this case the only symptom that has been developed is chest pain in the right chest, without developing a cough or shortness of breath. Conventional cross-sectional imaging diagnostic tools such as CT or MRI applied as a diagnosis and staging tools of bone and tissue sarcoma case, diagnostic review of biopsies and staging scans in supra-regional multi-disciplinary teams (MDT), aims to inform clinical management in line with national and international sarcoma guidelines¹¹. On CT scan, cavum thorax leiomyosarcoma shows a huge soft tissue tumor with heterogeneous enhancement because of bleeding, necrosis and other heterogeneous texture. Larger tumors can also push against the surrounding organs and can occasionally be invasive⁴. Combined F-FDG Positron Emission Tomography with CT (PET-CT) gives advantage as it provides anatomical and metabolic imaging combined in single examination. Leiomyosarcomas show enhancement on MRI, while they also show a high FDG uptake on PET-CT¹¹. In this case we perform a MDCT examination that shows a huge soft tissue tumor that expands to lower anterior mediastinum and pressing the right ventricle, in the abdominal region the tumor presses the liver and infiltrates the right anterior diaphragm.

In this case leiomyosarcoma in the chest wall is suspected due to primary leiomyosarcoma. Treatment using surgery is the first line treatment of leiomyosarcoma, with extensive resection with sufficient margin (2-3cm)¹². Despite the optimal local treatment, the risk of recurrence and metastasis is still high at approximately 40%^{3,8}. We perform a partial lower sternotomy extended to right anterior thoracotomy with preoperative embolization of the internal mammary artery as a feeding artery in this case. Management of chest tumors and their sequelae are uncommon indications for transarterial embolization. But more recently, vascular embolization has been increasingly performed by this indication¹³. Embolization of the feeding artery in the case of cancer surgery is indicated to minimize blood loss and also to reduce operative time compared to who does not do this procedure. The duration between embolization and surgery ranged from several hours to several days, the same day embolization and surgery showed significant reduction of blood loss, but for duration of surgery was not reduced significantly¹⁴. In this case embolization was performed on the same day with surgery, and there is a 500cc blood loss without any hemodynamic change in patient condition.

The optimal treatment for patients with thoracic leiomyosarcoma has not been defined. However, due to chemotherapy and radiotherapy resistance, surgery with wide negative margin becomes the first line therapy in the case of cavum thorax leiomyosarcoma^{4,12}. Although the benefit of surgical treatment, surgical treatment has many difficulties and requires special knowledge and technique because of anatomical and structural particularities. Local control of chest wall malignancy needs wide resection with tumor free margin. Wide resection of the chest wall however risks thoracic cavity failure and subsequent pulmonary failure¹⁰. The approach to access mediastinal tumor is Clamshell incision, median sternotomy, anterolateral and posterolateral sternotomy, and the median sternotomy is a common approach used because it provides better exposure to superior and anterior mediastinal lesion¹⁵. In this case we performed a sternotomy surgery to evacuate metastasis mass in this patient. This approach is chosen due to involvement of anterior mediastinal region by expansion of the tumor.

After evacuation of the tumor, the site of operation was reconstructed by a flap from abdominal muscle that was done by a plastic surgeon. The objective of reconstruction of the chest wall is to preserve normal chest wall mechanics and pulmonary function¹⁰. Chest wall reconstruction remains one of the greatest plastic surgery repair challenges. The needs of reconstruction of the chest wall due to tumor (primary or recurrence), infection, radiotherapy complication, and the less

common is due to trauma. A variety of myocutaneous flap that used to chest wall reconstruction, including transverse rectus abdominis muscle (TRAM) or vertical rectus abdominis muscle (VRAM), pectoralis major, latissimus dorsi, and trapezius muscle. Other muscles are used less frequently. Omental transposition is a second interesting option when the previous methods fail or, in the cases of recurrent infection, due to its rich vascularization. The abdominal rectus muscle flap, pedicled in the superior epigastric artery, is used to cover anterior or central defects of the hemithorax. This flap may be designed in a transverse (TRAM) or vertical (VRAM) form according to the orientation of the area requiring repair. It does not present a pedicle as reliable as the LDM or pectoralis major, and the amount of muscle in the flap is lower than in the other above-mentioned flaps, but it remains a good option, mainly when there are concerns regarding pedicle viability in the other flaps¹⁶.

Adjuvant therapy such as radiotherapy and chemotherapy commonly used in treatment of malignancy over the past few years. But many studies that show neither radiotherapy or chemotherapy does not show any benefit to reduce recurrence or metastasis in leiomyosarcoma patients, especially in the early stage of leiomyosarcoma (stage I and II)¹⁷⁻²⁰. When surgery margins were close, especially in high grade sarcoma, preoperative or postoperative radiotherapy becomes an important additional treatment, while the primary role of chemotherapy is in the treatment of metastatic disease¹². In this case we refer the patient to another hospital for radiotherapy and chemotherapy treatment that was not available in our center.

Conclusion

The uterine leiomyosarcoma diagnosis must be made as soon as possible with adequate diagnostic tools such as transvaginal ultrasonography, CT-scan, MRI, dilated and curettage (D&C), endometrial biopsy, or PET- scan. The early diagnosis and surgery as the only option treatment could give better prognosis for patients and enhance the survival rate and depress metastasis probability. The use of preoperative embolization will reduce the risk of massive bleeding and operative time. Adjuvant therapy such as chemotherapy and radiotherapy in stage I and II should be postponed and in advance metastasis leiomyoma should be consulted to the patient due to lack of benefit evidence.

REFERENCE

- [1] Gootee J, Sioda N, Aurit S, Curtin C, Silberstein P. Important prognostic factors in leiomyosarcoma survival: a National Cancer Database (NCDB) analysis. *Clinical and Translational Oncology*. 2020 Jun 1;22(6):860–9.
- [2] Savu C, Melinte A, Gibu A, Varban S, Diaconu C, Socea B, et al. Primary leiomyoma of the visceral pleura: An unexpected occurrence. *In Vivo (Brooklyn)*. 2021 Aug 1;35(4):2457–63.
- [3] Delisle M, Alshamsan B, Nagaratnam K, Smith D, Wang Y, Srikanthan A. Metastasectomy in Leiomyosarcoma: A Systematic Review and Pooled Survival Analysis. Vol. 14, *Cancers*. MDPI; 2022.
- [4] Yamamoto S, Hirose M, Oyaizu T, Muramatsu A, Suzuki M, Ohta S. Leiomyosarcoma of the chest wall mimicking schwannoma resected by a video-assisted thoracoscopic approach: a case report. *J Surg Case Rep*. 2022 Jan 1;2022(1).
- [5] Yadav SP, Patil S, Puntambekar A, Deshpande R. Conjunctival Metastasis from Leiomyosarcoma of Anterior Chest Wall. *Journal of Clinical Oncology and Therapeutics*. 2020;2(2).
- [6] Mangla A, Udit ;, Affiliations Y. *Cancer, Leiomyosarcoma* [Internet]. 2019. Available from: <https://www.ncbi.nlm.nih.gov/books/NBK551667/?report=printable>
- [7] George S, Serrano C, Hensley ML, Ray-Coquard I. Soft Tissue and Uterine Leiomyosarcoma. *Journal of Clinical Oncology*. 2018 Jan 10;36(2):144–50.
- [8] L. Byar MABBK, Fredericks MMT. Uterine Leiomyosarcoma. *J Adv Pract Oncol*. 2022 Jan 1;13(1):70–6.
- [9] Friedman CF, Hensley ML. Options for Adjuvant Therapy for Uterine Leiomyosarcoma. Vol. 19, *Current Treatment Options in Oncology*. Springer New York LLC; 2018.
- [10] Asanuma K, Tsujii M, Hagi T, Nakamura T, Kita K, Shimamoto A, et al. Full-thickness chest wall resection for malignant chest wall tumors and postoperative problems. *Front Oncol*. 2023;13.
- [11] Macpherson RE, Pratap S, Tyrrell H, Khonsari M, Wilson S, Gibbons M, et al. Retrospective audit of 957 consecutive 18F-FDG PET–CT scans compared to CT and MRI in 493 patients with different histological subtypes of bone and soft tissue sarcoma. *Clin Sarcoma Res*. 2018 Dec;8(1).
- [12] Rastrelli M, Tropea S, Spina R, Costa A, Stramare R, Mocellin S, et al. A Case of “en bloc” Excision of a Chest Wall Leiomyosarcoma and Closure of the Defect with Non-Cross-Linked Collagen Matrix (Egis®). *Case Rep Oncol*. 2016 Oct 20;9(3):655–60.
- [13] Lorenz JM, Navuluri R. Embolization of Chest Neoplasms: The Next Frontier in Interventional Oncology? *Semin Intervent Radiol*. 2019;36(3):176–82.
- [14] Katagiri K, Shiga K, Ikeda A, Saito D, Oikawa S ichi, Tshuchida K, et al. Effective, same-day preoperative embolization and surgical resection of carotid body tumors. *Head Neck*. 2019 Sep 1;41(9):3159–67.
- [15] De Llano JG, Mijares MF, Vasudevan V, Arrangoiz R, Sastry A, Cruz FD la, et al. Mediastinal Liposarcoma: Case Report and Literature Review. *J Cancer Ther*. 2021;12(04):208–20.
- [16] PESSOA SGDP, MUNIZ VDV, MUNIZ ADV, BARRETO PRA, ALCÂNTARA RJA DE, MATOS JRF. Chest wall reconstruction using abdominal rectus and latissimus dorsi muscle flaps: case report. *Revista Brasileira de Cirurgia Plástica (RBCP) – Brazilian Journal of Plastic Surgery*. 2016;31(1):129–32.

- [17] Rizzo A, Nannini M, Astolfi A, Indio V, De Iaco P, Perrone AM, et al. Impact of chemotherapy in the adjuvant setting of early stage uterine leiomyosarcoma: A systematic review and updated meta-analysis. *Cancers (Basel)*. 2020 Jul 1;12(7):1–12.
- [18] Patel D, Handorf E, Von Mehren M, Martin L, Movva S. Adjuvant chemotherapy in uterine leiomyosarcoma: Trends and factors impacting usage. *Sarcoma*. 2019;2019.
- [19] Chae SH, Shim SH, Chang M, Choi AY, Kang GG, Lee SJ, et al. Effect of adjuvant therapy on the risk of recurrence in early-stage leiomyosarcoma: A meta-analysis. Vol. 154, *Gynecologic Oncology*. Academic Press Inc.; 2019. p. 638–50.
- [20] Qian SJ, Wu JQ, Wang Z, Zhang B. Surgery plus chemotherapy improves survival of patients with extremity soft tissue leiomyosarcoma and metastasis at presentation. *J Cancer*. 2019;10(10):2169–75.