

DO: <https://doi.org/10.53555/yvtzn638>Publication URL: <https://nnpub.org/index.php/MHS/article/view/1938>

RISK OF HYPERTENSION WITH MULTICYSTIC KIDNEY DISEASE : A SYSTEMATIC REVIEW

Rizkia Amal Ramadhani

Banyumanik 1 General Hospital, Semarang, Indonesia

Corresponding Author:
ramadhani613@gmail.com

ABSTRACT

Background: Multicystic dysplastic kidney (MCDK) is a congenital cystic kidney disease that can be incidentally seen during the antenatal ultrasound. The condition is most commonly asymptomatic. The clinical presentation is usually characterized by multiple small cysts or a single dominating cyst in the fetal kidney depending on the type of MCDK. Most cases undergo spontaneous involution, and complications like hypertension, infection, and malignancy are rare. Methods: By comparing itself to the standards set by the Preferred Reporting Items for Systematic Review and Meta-Analysis (PRISMA) 2020, this study was able to show that it met all of the requirements. So, the experts were able to make sure that the study was as up-to-date as it was possible to be. For this search approach, publications that came out between 2013 and 2023 were taken into account. Several different online reference sources, like Pubmed and SagePub, were used to do this. It was decided not to take into account review pieces, works that had already been published, or works that were only half done. Result: In the PubMed database, the results of our search brought up 563 articles, whereas the results of our search on SagePub brought up 5 articles. The results of the search conducted for the last year of 2013 yielded a total 6 articles for PubMed and 3 articles for SagePub. In the end, we compiled a total of 5 papers, 2 of which came from PubMed and 1 of which came from SagePub. We included five research that met the criteria. Conclusion: Although the risk of hypertension in MCKD is low, the results of this study do not allow firm recommendations on the frequency and duration of blood pressure measurement follow up for these children. Large prospective cohort studies with a very long duration of follow up are needed.

Keyword: *Hypertension, MCKD, multicystic kidney disease, risk*

INTRODUCTION

Multicystic dysplastic kidney (MCDK) is a renal dysplasia characterized by the presence of multiple cysts that are noncommunicating, varying in size, separated by dysplastic parenchyma that consume the renal cortex resulting in a nonfunctional kidney with the absence of a normal pelvocaliceal system. It is due to the atresia of the ureteral bud system during the metanephric stage of uterine development with failure of normal nephrogenesis. The incidence of MCDK is approximately 1:4300 of live births, with males being affected more often than females. MCDK can be familial disease but most often occurs sporadically. Most cases of MCDK are detected during fetal ultrasonography and are reported as early as 15 weeks gestation. Studies have shown that MCDK occurs 53% of the time in the left kidney and 47% of the time in the right kidney.¹

MCDK is a developmental disorder that occurs when the urinary tract is obstructed during embryogenesis. The obstruction leads to an abnormal metanephric-mesenchymal differentiation, which causes MCDK. These non-functional cysts most often undergo complete agenesis and are therefore commonly asymptomatic. However, they can also be associated with complications or malformations such as vesicoureteric reflux (VUR), cryptorchidism, and other genital abnormalities.²

MCDK can be unilateral or bilateral. Unilateral MCDK is more common than bilateral MCDK and is more commonly seen in male fetuses. The incidence of unilateral MCDK is roughly 1:4000, with a predisposition for the left kidney. Bilateral MCDK is more likely to be linked to non-renal problems and is incompatible with life.²

MCDK is isolated in approximately 70% to 75% of cases. Many cases include associated anomalies of the genitourinary tract, including contralateral renal agenesis, which occurs in approximately 15% of cases. Other genitourinary abnormalities observed in the contralateral kidney include urinary tract obstruction and vesicoureteral reflux; abnormalities of the genitalia can also be present. Extrarenal malformations can be seen in approximately 25% of cases. These may include cardiac, central nervous system, and, gastrointestinal anomalies; omphalocele; and vertebral and skeletal malformations. The presence of additional anomalies raises the concern for a possible genetic etiology.³

MCDK can be sporadic, non-familial, or rarely associated with a genetic syndrome. MCDK can, in some cases, have a genetic etiology and has also been found to be associated with syndromes such as Meckel-Gruber syndrome, Joubert syndrome, and Zellweger syndrome.⁴

Whenever it is symptomatic, MCDK presents with symptoms like flank pain, recurrent UTI (secondary to VUR), hypertension, and/or a palpable mass. It may present as an incidental finding in the early years of life when infants undergo ultrasounds for other indications. With the rise in the number of comprehensive prenatal anatomy ultrasounds performed around 20 weeks of pregnancy, diagnosis is frequently also made in the fetus while it is still in utero.⁴

Complete spontaneous resolution of MCDK can be seen in as many as 60% of cases. Infection, hypertension, and malignancy of MCDK are some of the less frequent complications of MCDK. It can be associated with contralateral renal abnormalities like VUR, pelviureteric junction obstruction, vesicoureteric junction obstruction, renal agenesis, and hypoplasia.²

Unilateral isolated MCDK with a normal contralateral kidney is associated with an excellent prognosis. A report outcomes in a cohort of children with isolated unilateral MCDK diagnosed prenatally and found that there was complete involution of MCDKs by 10 years in more than 50% of those affected. There was no hypertension, malignancy, or significant proteinuria noted long term. Surgical removal is indicated when the affected kidney is enlarging or if the mass effect from the MCDK impacts respiration or feeding in the neonate.³

In contrast, bilateral MCDK results in severe impairment of renal function that will result in oligohydramnios or anhydramnios. Early-onset anhydramnios and oligohydramnios will result in varying degrees of pulmonary hypoplasia and significant morbidity and mortality. The combination of both renal failure and pulmonary hypoplasia is lethal. Postnatal evaluation by both pediatric nephrology and urology specialists is recommended as ongoing surveillance may be needed.³

METHODS

Protocol

By following the rules provided by Preferred Reporting Items for Systematic Review and Meta-Analysis (PRISMA) 2020, the author of this study made certain that it was up to par with the requirements. This is done to ensure that the conclusions drawn from the inquiry are accurate.

Criteria for Eligibility

For the purpose of this literature review, we review assessed risk of hypertension for multicystic kidney disease. This is done to provide an explanation and improve the handling of treatment at the patient. As the main purpose of this paper, to show the relevance of the difficulties that have been identified as a whole.

In order for researchers to take part in the study, it was necessary for them to fulfil the following requirements: 1) The paper needs to be written in English. In order for the manuscript to be considered for publication, it needs to meet both of these requirements. 2) The studied papers include several that were published after 2013, but before the time period that this systematic review deems to be relevant. Examples of studies that are not permitted include editorials, submissions that do not have a DOI, review articles that have already been published, and entries that are essentially identical to journal papers that have already been published.

Search Strategy

We used "multicystic kidney diseases" as keywords. The search for studies to be included in the systematic review was carried out using the PubMed and SagePub databases by inputting the words: Although it is reassuring to realise that the risk of hypertension in MCKD is low, the results of this study do not allow firm recommendations on the frequency and duration of blood pressure measurement follow up for these children. More robust risk estimates with risk stratification by age bands are needed, and can only be achieved through large prospective cohort studies with a very long duration of follow up. Such studies would also be able to provide information on whether involution of the affected kidney modifies such a risk used in searching the literature.

Data retrieval

After reading the abstract and the title of each study, the writers performed an examination to determine whether or not the study satisfied the inclusion criteria. The writers then decided which previous research they wanted to utilise as sources for their article and selected those studies. After looking at a number of different research, which all seemed to point to the same trend, this conclusion was drawn. All submissions need to be written in English and can't have been seen anywhere else.

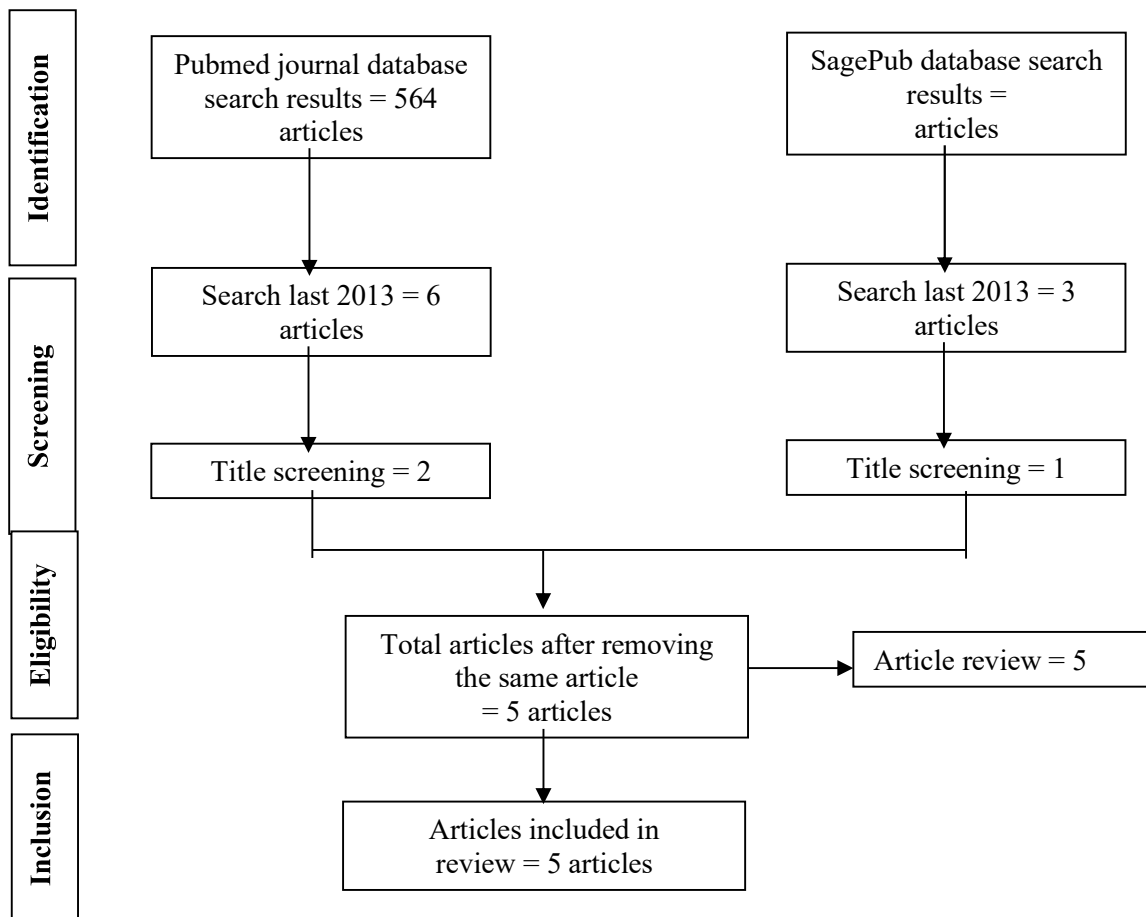


Figure 1. Article search flowchart

Only those papers that were able to satisfy all of the inclusion criteria were taken into consideration for the systematic review. This reduces the number of results to only those that are pertinent to the search. We do not take into consideration the conclusions of any study that does not satisfy our requirements. After this, the findings of the research will be analysed in great detail. The following pieces of information were uncovered as a result of the inquiry that was carried out for the purpose of this study: names, authors, publication dates, location, study activities, and parameters.

Quality Assessment and Data Synthesis

Each author did their own study on the research that was included in the publication's title and abstract before making a decision about which publications to explore further. The next step will be to evaluate all of the articles that are suitable for inclusion in the review because they match the criteria set forth for that purpose in the review. After that, we'll determine which articles to include in the review depending on the findings that we've uncovered. This criteria is utilised in the process of selecting papers for further assessment. In order to simplify the process as much as feasible when selecting papers to evaluate. Which earlier investigations were carried out, and what elements of those studies made it appropriate to include them in the review, are being discussed here.

RESULT

In the PubMed database, the results of our search brought up 564 articles, whereas the results of our search on SagePub brought up articles. The results of the search conducted for the last year of 2013 yielded a total 6 articles for PubMed and 3 articles for SagePub. In the end, we compiled a total of 5 papers, 2 of which came from PubMed and 1 of which came from SagePub. We included five research that met the criteria.

Sharada, et al⁵ (2014) showed that that the main risk factor for developing hypertension is contralateral kidney damage. In our study, even though the contralateral renal anomalies were high, no child developed persistent hypertension. In conclusion, long term nephrological follow up is needed in children with MCDK. As renal functions depend on the contralateral functioning kidney, its anomalies need to be detected early and managed appropriately.

Dorgan, et al⁶ (2014) showed that abnormalities in the contralateral kidney in patients with MCDK increase the risk of renal failure. An initial investigation for associated urinary tract malformations should be done and the growth and function of the contralateral kidney, hypertension, and proteinuria should be monitored in all children with MCDK.

Table 1. The literature include in this study

Author	Origin	Method	Sample	Result
Sharada et al, 2014⁵	India	Retrospective study	47 patients	Antenatal diagnosis of multicystic dysplastic kidney was made in 34 (72.3%) patients. On follow up of 31 children for more than 12 months, 21 (68%) had involution, 4 [13%] had non-regression, and 4 (13%) were nephrectomized. Vesico-ureteric reflux (n=13; 28%) was the commonest renal abnormality. The serum creatinine values were higher (P=0.006) in children with contralateral reflux. Sub-nephrotic proteinuria was noted in 9 (29%) and was significantly associated with complete involution (P=<0.023). None of the patients developed hypertension and 2 (6.4%) had renal failure.
Dogan et al, 2014⁶	Turkey	Retrospective study	59 patients	The median age of the patients (boys 52.5%) was 31 months (range: 6-197) and the median follow-up period was 23 months (range: 6-111). Forty-two (71.2%) patients were diagnosed antenatally. The MCDKs were found more often on the right side (55.9%). The most frequently associated urological abnormality was contralateral vesicoureteral reflux (VUR) (26.6%). A total of 3 (5%) patients developed chronic renal insufficiency (CRI), 2 of whom had grade IV and V VUR; the other patient with CRI had a small and hyperechogenic contralateral kidney, suggesting dysplasia-hypoplasia, without any urological anomalies on imaging studies. The size of MCDK was unchanged in 20 (34%), had regressed in 26 (44%), and had increased in 9 (15.3%) patients. Total involution was documented in 4 (6.7%) patients. Compensatory hypertrophy occurred in 36/45 (80%) patients, with a mean age of 19.2±8.3 months. Proteinuria and hypertension were detected in 1 (1.7 %) patient each.
Moralioglu et al, 2014³	USA	Retrospective study	64 patients	MDK was detected by antenatal ultrasound in 64

				<p>(94.1%) of the patients. Ten patients had (14.7%) additional urological anomalies in contralateral kidney. Vesicoureteral reflux was found in five patients (7.3%). Other urological anomalies were megaureter (two), cortical renal cyst (two), ureteropelvic junction obstruction (one), and renal ectopy (one). Urinary tract infection was detected in 14 (20.5%) patients. Four (5.9%) patients had hypertension. Compensatory hypertrophy was detected in 29 (42.6%) patients. Eight (11.8%) of these 29 patients had glomerular hyperfiltration and three (4.4%) of these eight patients also had proteinuria. Follow-up ultrasound revealed complete involution in 19 (35.8%) patients. Nephrectomy was performed in 15 (22.0%) patients. Indications of nephrectomy were, recurrent urinary infection (four), hypertension (three), ureterocele (two), renal calculi (one), flank pain (one), hematuria (one), persistent large cystic kidney (three), and atypical US findings (two).</p>
--	--	--	--	--

Moralioglu, et al (2014) showed that in patients with MDK, depending on the clinical, laboratory, and radiological findings, appropriate timing of operation by multidisciplinary approach is important for early detection and treatment of any possible complications.

DISCUSSION

Multicystic dysplastic kidney (MCDK) is a common pediatric renal condition that is characterized by multiple non-communicating cysts in the kidney with little or no functioning renal parenchyma. It is the commonest cause of renal cystic disease in neonates.⁷

MCDK is the second most common cause of abdominal mass in neonates. While unilateral MCDK has a far better prognosis, is typically asymptomatic, and involutes over time, bilateral MCDK is mostly incompatible with life. Various factors have been proposed as the causative factors of MCDK. These include genetic factors, intrauterine infections, and teratogens. MCDK can occasionally be linked to nonrenal problems, the most frequent of which are genital, cardiac, and musculoskeletal issues. Additionally, MCDK has been linked to genetic disorders such as Waardenburg syndrome, Turner syndrome, and Trisomy 21. Many cases of MCDK are diagnosed before birth, sometimes as early as the fifteenth week of pregnancy when many tiny cysts begin to appear.⁸

The non-functional renal parenchyma is classically fibrous with a lobulated appearance that consists of numerous internal cysts of various sizes and shapes. Two main types of MCDK have been described. These include the pelvic-infundibular variant, which was also seen in our case, is more common, and is associated with multiple small clusters of non-communicating cysts with atresia of the renal pelvis and ureter. The second type is the hydronephrotic-obstructive type, which is seen as a dominant cyst in the renal pelvis on scans.⁷

In order to rule out any connections with the ureter and among themselves, real-time imaging is very helpful. Various MRI sequences, including steady-state free precession (SSFP), T2-weighted imaging, and diffusion-weighted imaging, are used to illustrate MCDK and the affiliated abnormalities clearly. A mercaptoacetyl triglycine (MAG3) or diethylenetriamine pentaacetate (DTPA) scan is also particularly helpful to check for concomitant obstructive uropathy

in the hydronephrotic variant of MCDK. Up to 60% of cases can undergo complete spontaneous involution and although resolution is most common in the first three years of life, this may take up to 10 years to happen.⁹ Conservative management with follow-up is therefore the approach followed by most clinicians. Serial ultrasonography is used to follow up on the patients until spontaneous involution occurs. MCDK can be associated with various genitourinary anomalies such as VUR, pelviureteric stenosis and obstruction, ureterocele, and cryptorchidism. Of these, VUR is by far the most common complication, occurring in between 16% and 21% of the contralateral kidneys of affected patients. Patients with a urinary tract infection or ultrasonographic signs of VUR, like urinary tract dilatation, may benefit from further workup using a voiding cystourethrography (VCUG).^{9,10}

The risk of hypertension in MCDK is less than in the average population. The rate of malignant transformation of MCDK is minimal. This low risk of malignant transformation of an MCDK also raises questions about the usefulness of preventative surgical removal. Recurrent UTI, sudden or progressive increase in the size of the kidney, and worsening or persistent flank pain are some of the indications of surgery.⁸

Follow-up ultrasonography is recommended at 32 weeks of gestation to evaluate the contralateral kidney, fetal growth, and amniotic fluid volume. Fetal echocardiography should be considered given the association of MCDK with other anomalies. Consultation with pediatric nephrology and urology specialists may be considered, particularly when there is concern for an anomaly in the contralateral kidney. Insufficient evidence exists regarding any potential benefit of antenatal testing, and timing and mode of delivery should be based on usual obstetrical indications.³ With antenatal ultrasonography not available in the earlier years and its diagnostic accuracy progressively improving since its early use, it is likely that selection bias has occurred. In addition, antenatally diagnosed cases of MCKD (with variable degree of accuracy throughout the study period) were grouped together with other postnatally diagnosed cases (such as children with an abdominal mass), although the natural history and the prognosis for hypertension might not be similar between these two groups.

Without a knowledge of the age when the hypertension was diagnosed, calculation of hypertension risk by age band is not possible, not enabling therefore an estimation of the duration of surveillance for that complication in children with MCKD. Another inherent limitation to the study was that the available data in the reports precluded any actuarial or "survival"-type data analysis, or the use of multivariate analysis such as logistic regression or proportional hazard methods to take into account the role of the many potential confounders.

Publication bias and reporting bias may also have occurred, as only few studies have looked at and reported outcomes of MCKD in a systematic manner, in comparison to virtually all the cases of hypertension associated with MCKD being isolated case reports. As obviously many more series of children with MCKD have never been reported, the true number and proportion of children with MCKD who did not develop hypertension is likely to be even higher, making the estimated maximum incidence rate of hypertension in MCKD even lower than the results of this study. As it is likely that a significant percentage of unilateral renal agenesis cases are in fact MCKD which involute, the true incidence of MCKD is likely to be even higher than currently reported, resulting in an even lower risk of hypertension than theoretically calculated.¹⁰

The precision estimate of this risk could be refined further. While further information from the American registry would be very helpful, a national, or a European registry for children with MCKD needs to be developed, with systematic and uniform prospective long term follow up of affected children, including those where MCKD involutes. Further breakdown of cases between those diagnosed antenatally and those diagnosed later may also clarify any differences in the natural history or prognosis for hypertension between these two subgroups. Such long term cohort studies are likely to be difficult: with hypertension being relatively rare, a very large number of children with MCKD will need to be prospectively followed up for a very long period, well into adulthood, with the inherent risk of loss to follow up dardised in the reports analysed in the current study, unlike the prospective studies undertaken recently in the general paediatric population, possibly resulting in a misclassification bias. Furthermore, the incidence of hypertension with MCKD in older children is not well known as the longest follow up in the studies reported in this analysis was 13 years only, while the prospective studies in the general population included older children up to adolescence, making any comparison between these two groups unrealistic. Only long term follow up studies of cohorts with MCKD could establish if that incidence increases with age and could compare that risk with the incidence of hypertension in the general population. Despite these drawbacks, although it may not be lower, it is reassuring that the risk of hypertension with MCKD does not seem to be higher than the risk in the general paediatric population.

Although the risk of hypertension in such children was found to be low, the occurrence of late onset of hypertension secondary to hyperperfusion injury of the remaining kidney remains theoretically possible. Although this risk, if it does indeed exist, can only be evaluated by undertaking large cohort studies followed up for decades, it justifies in the meantime the need for ongoing blood pressure follow up for these children.

Although it is reassuring to realise that the risk of hypertension in MCKD is low, the results of this study do not allow firm recommendations on the frequency and duration of blood pressure measurement follow up for these children. More robust risk estimates with risk stratification by age bands are needed, and can only be achieved through large

prospective cohort studies with a very long duration of follow up. Such studies would also be able to provide information on whether involution of the affected kidney modifies such a risk

CONCLUSION

MCDK is one of the most commonly seen genitourinary abnormalities that can be noted in midgestation. Prognosis is dependent on whether the lesion is unilateral or bilateral, and the presence of associated abnormalities in the contralateral kidney or extrarenal abnormalities impact outcomes. The presence of extrarenal findings raises concern for a possible genetic etiology. Isolated unilateral MCDK has an excellent prognosis both in utero and postnatally. Most cases resolve over time without the need for surgical intervention.

Although the risk of hypertension in MCKD is low, the results of this study do not allow firm recommendations on the frequency and duration of blood pressure measurement follow up for these children. Large prospective cohort studies with a very long duration of follow up are needed.

REFERENCE

- [1] Cooper CJ, Said S, Khalilullah S, Salameh HJ, Hernandez GT. Multicystic dysplastic kidney complicated by pyelonephritis. *Am J Case Rep* [Internet]. 2013 [cited 2023 Nov 11];14:412–5. Available from: <https://www.ncbi.nlm.nih.gov/pmc/articles/PMC3864172/>
- [2] Kopac M, Kordic R. Associated Anomalies and Complications of Multicystic Dysplastic Kidney. *Pediatr Rep* [Internet]. 2022 [cited 2023 Nov 11];14(3):375–9. Available from: <https://www.ncbi.nlm.nih.gov/pmc/articles/PMC9504218/>
- [3] Chetty S. Multicystic dysplastic kidney. *Am J Obstet Gynecol*. 2021 Nov 1;225(5):B21–2.
- [4] Scala C, McDonnell S, Murphy F, Maggiore ULR. Diagnostic accuracy of midtrimester antenatal ultrasound for multicystic dysplastic kidneys. *Observational Study* [Internet]. 2017 [cited 2023 Nov 11];50(4):464–9. Available from: <https://pubmed.ncbi.nlm.nih.gov/27643400/>
- [5] Sharada S, Vijayakumar M, Udani A. Multicystic Dysplastic Kidney: A Retrospective Study. Vol. 641, *INDIAN PEDIATRICS*. 2014.
- [6] Dogan CS, Torun-Bayram M, Aybar MD. Unilateral multicystic dysplastic kidney in children. *Turk J Pediatr* [Internet]. 2014 [cited 2023 Nov 11];56(1):75–9. Available from: <https://pubmed.ncbi.nlm.nih.gov/24827951/>
- [7] Chaubal R, Pokhriyal SC, Deshmukh A, Gupta U, Chaubal N. Multicystic Dysplastic Kidney Disease: An In-Utero Diagnosis. *Cureus* [Internet]. 2023 [cited 2023 Nov 11];15(4):377–86. Available from: <https://www.ncbi.nlm.nih.gov/pmc/articles/PMC10195076/>
- [8] Yadav P, Sureka SK, Ansari MS, Soni R, Lal H. Large Multicystic Dysplastic Kidney Mimicking a Large Cystic Renal Neoplasm. *J Clin Diagn Res* [Internet]. 2017 [cited 2023 Nov 11];03–4. Available from: <https://www.ncbi.nlm.nih.gov/pmc/articles/PMC5483747/>
- [9] Sarhan OM, Alghanbar M, Alsulaim A, Alharbi B, Alotay A, Nakshabandi Z. Multicystic dysplastic kidney: Impact of imaging modality selection on the initial management and prognosis. *J Pediatr Urol* [Internet]. 2014 [cited 2023 Nov 11]; Available from: <https://pubmed.ncbi.nlm.nih.gov/24731390/>
- [10] Kopač M, Kordič R. Associated Anomalies and Complications of Multicystic Dysplastic Kidney. *Pediatr Rep*. 2022 Sep 1;14(3):375–9.