

# OSTEOSYNTHESIS OF FRACTURES NECK FEMUR: A SYSTEMATIC REVIEW

**Dhanang Susilo\***

*\*Faculty of Medicine, Sultan Agung Islamic University, Indonesia*

**\*Corresponding Author:**

*trio.periang@gmail.com*

---

## **Abstract**

**Introduction:** *US hip fractures exceed 250,000 each year. Femoral neck and intertrochanteric fractures are equally diagnosed. This number will double by 2050. Cannulated screws, hip screw systems, proximal femur plates, and cephalomedullary nails can treat femoral neck fractures. These procedures are evaluated for biomechanical stability.*

**The aim:** *This article discusses osteosynthesis in patients with femoral neck fractures.*

**Methods:** *By comparing itself to the standards set by the Preferred Reporting Items for Systematic Review and Meta-Analysis (PRISMA) 2020, this study was able to show that it met all of the requirements. So, the experts were able to make sure that the study was as up-to-date as it was possible to be. For this search approach, publications that came out between 2013 and 2023 were taken into account. Several different online reference sources, like Pubmed and SagePub, were used to do this. It was decided not to take into account review pieces, works that had already been published, or works that were only half done.*

**Result:** *In the PubMed database, the results of our search brought up 123 articles, whereas the results of our search on SagePub brought up 72 articles. The results of the search conducted for the last year of 2013 yielded a total 75 articles for PubMed and 16 articles for SagePub. In the end, we compiled a total of 24 papers, 17 of which came from PubMed and seven of which came from SagePub. We included five research that met the criteria.*

**Conclusion:** *Osteosynthesis is the medical word for joining fracture ends using metal plates, pins, rods, wires, or screws. It's called "osteosynthesis." After a maxillofacial injury, fracture reduction and stabilisation are necessary to restore facial tissues to their pre-injury state. Especially after maxillofacial trauma. Primary arthroplasty may be considered for Garden-I and II femoral neck fractures with posterior tilt  $\geq 20^\circ$ , especially among older patients.*

**Keyword:** *Femur neck fracture; Fixation; Osteosynthesis*

## INTRODUCTION

There are over 250,000 cases of hip fractures diagnosed each year in the United States. These diagnoses are split evenly between femoral neck and intertrochanteric fractures. It is anticipated that by the year 2050, this number will have increased by a factor of two.<sup>1</sup> Women account for seventy-five percent of all hip fractures. The incidence is extremely rare in patients younger than 30 years old and is primarily connected with high-energy trauma. The majority are caused by low-energy falls, and the victims are typically elderly people with an average age of 72 years.<sup>2</sup>

Female gender, being of white race, growing age, being in poor health, smoking and drinking, having a history of a previous fracture, having a history of falling, and having a low oestrogen level are all risk factors.<sup>2,3</sup> Even though hip joint contact forces described in the literature easily exceed 500% BW and can reach 4000–5000 N of load during daily activities and healthy people rarely break it. Fractures of femoral neck happen when the hip is bent and there is a vertical contact along the axis of femoral shaft. They can also happen when the greater trochanter is hit from the side or when the leg is turned, which usually happens when the hip is bent and weight is put on hip joint.<sup>4,5</sup>

The femoral neck region is typically where hip fractures occur, and the risk of a fracture occurring in the trochanteric region increases with increasing age. Fractures in the hip joint tend to be located in this location. As a result, hip fractures in younger adults are significantly more prone to develop in the portion of the hip known as the neck compared to the hip's other sections. According to the Pauwels classification, young people more typically display fractures of type III that are vertically orientated, more unstable, and require correct reduction and stable internal fixation.<sup>6,7</sup>

When treating young adults with a femoral neck fracture, precise reduction and stable internal fixation are essential. Cannulated screws, hip screw systems, proximal femur plates, and cephalomedullary nails are some of the different approaches that are available for fracture fixation at the femoral neck. These procedures are reviewed in terms of how well they are able to give biomechanical stability. When a fracture is mechanically unstable, a load-bearing implant, such as hip screws, with antirotational screws, or intramedullary nails, is required to stabilise the fracture.<sup>8-10</sup> This article discusses osteosynthesis in patients with femoral neck fractures.

## METHODS

### Protocol

By following the rules provided by Preferred Reporting Items for Systematic Review and Meta-Analysis (PRISMA) 2020, the author of this study made certain that it was up to par with the requirements. This is done to ensure that the conclusions drawn from the inquiry are accurate.

### Criteria for Eligibility

For the purpose of this literature review, we compare and contrast the procedures of osteosynthesis in patients with femoral neck fractures. As the primary purpose of this piece of writing, demonstrating the relevance of the difficulties that have been identified will take place throughout its entirety. In order for researchers to take part in the study, it was necessary for them to fulfil the following requirements: 1) The paper needs to be written in English, and it will discuss about osteosynthesis in patients with femoral neck fractures. In order for the manuscript to be considered for publication, it needs to meet both of these requirements. 2) The studied papers include several that were published after 2013, but before the time period that this systematic review deems to be relevant. Examples of studies that are not permitted include editorials, submissions that do not have a DOI, review articles that have already been published, and entries that are essentially identical to journal papers that have already been published.

### Search Strategy

We used "osteosynthesis" and "femoral neck fractures" as keywords. The search for studies to be included in the systematic review was carried out from July, 28<sup>th</sup> 2023 using the PubMed and SagePub databases by inputting the words: (*"fracture fixation, internal"[MeSH Terms] OR ("fracture"[All Fields] AND "fixation"[All Fields] AND "internal"[All Fields]) OR "internal fracture fixation"[All Fields] OR "osteosynthesis"[All Fields]) AND ("femoral neck fractures"[MeSH Terms] OR ("femoral"[All Fields] AND "neck"[All Fields] AND "fractures"[All Fields]) OR "femoral neck fractures"[All Fields]) AND (y\_10[Filter]) AND (clinicaltrial[Filter])*) used in searching the literature.

### Data retrieval

After reading the abstract and the title of each study, the writers performed an examination to determine whether or not the study satisfied the inclusion criteria. The writers then decided which previous research they wanted to utilise as sources for their article and selected those studies. After looking at a number of different research, which all seemed to point to the same trend, this conclusion was drawn. All submissions need to be written in English and can't have been seen anywhere else.

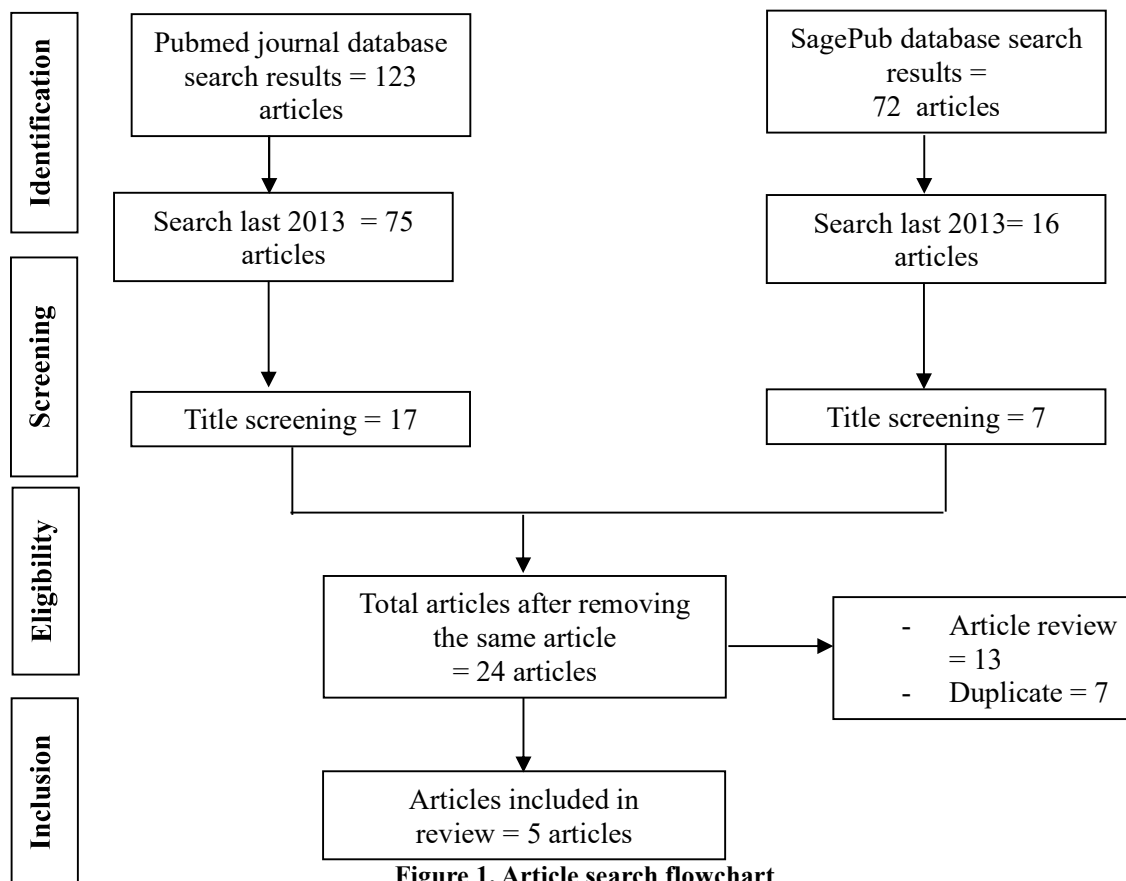


Figure 1. Article search flowchart

Only those papers that were able to satisfy all of the inclusion criteria were taken into consideration for the systematic review. This reduces the number of results to only those that are pertinent to the search. We do not take into consideration the conclusions of any study that does not satisfy our requirements. After this, the findings of the research will be analysed in great detail. The following pieces of information were uncovered as a result of the inquiry that was carried out for the purpose of this study: names, authors, publication dates, location, study activities, and parameters.

**Quality Assessment and Data Synthesis**

Each author did their own study on the research that was included in the publication's title and abstract before making a decision about which publications to explore further. The next step will be to evaluate all of the articles that are suitable for inclusion in the review because they match the criteria set forth for that purpose in the review. After that, we'll determine which articles to include in the review depending on the findings that we've uncovered. This criteria is utilised in the process of selecting papers for further assessment. In order to simplify the process as much as feasible when selecting papers to evaluate. Which earlier investigations were carried out, and what elements of those studies made it appropriate to include them in the review, are being discussed here.

**RESULT**

In the PubMed database, the results of our search brought up 123 articles, whereas the results of our search on SagePub brought up 72 articles. The results of the search conducted for the last year of 2013 yielded a total 75 articles for PubMed and 16 articles for SagePub. In the end, we compiled a total of 24 papers, 17 of which came from PubMed and seven of which came from SagePub. We included five research that met the criteria.

Cuellar, et al (2022)<sup>11</sup> conducted a study with ten matched cadaveric pairs (20 femurs) were randomly assigned to two screw fixation groups. Group 1 (Hybrid) utilized one fully threaded calcar screw & two partially threaded superior screws. Group 2 (PT) utilized all partially threaded screws. Construct stiffness was 2848 ± 344 N/mm in PT vs. 2767 ± 665 for Hybrid (P = 0.628). Load to failure demonstrated, hybrid superiority with max cycles to failure (3797 ± 400 cycles) vs. (2981 ± 856 cycles in PT) (p = 0.010), and max load prior to failure (3290 ± 196 N) vs. (2891 ± 421 N in PT) (p = 0.010). No significant difference in bone mineral density was noted in any of the specimens.

Okike, et al (2019)<sup>12</sup> showed 67 (12.1%) had posterior tilt ≥20° and 488 (87.9%) had posterior tilt <20°. Overall, 73 (13.2%) of 555 patients underwent subsequent arthroplasty in the 24-month follow-up period. In the multivariable analysis, patients with posterior tilt ≥20° had a significantly higher risk of subsequent arthroplasty compared with those with posterior tilt <20° (22.4% [15 of 67] compared with 11.9% [58 of 488]; hazard ratio [HR] = 2.22; 95% confidence interval [CI] = 1.24 to 4.00; p = 0.008). The other factor associated with subsequent arthroplasty was age ≥80 years (p = 0.03).

**Table 1. The literature include in this study**

Author	Origin	Method	Sample Size	Result
Cuellar, 2022 <sup>11</sup>	United State of America	Randomized clinical trial (RCT)	20 femurs	The use of hybrid screw design led to substantially stronger structures, which were able to withstand a larger axial load and more cycles before failing. The length stable construct that is provided by the favourable mechanical qualities exhibited utilising a completely threaded inferior calcar screw may minimise the frequent complications of excessive femoral neck shortening, varus collapse, and poor functional result.
Okike, 2019 <sup>12</sup>	United State of America	Retrospective cohort study	555 patients	this analysis of patients with Garden-I and II femoral neck fractures, posterior tilt $\geq 20^\circ$ was associated with a significantly increased risk of subsequent arthroplasty. Primary arthroplasty may be considered for Garden-I and II femoral neck fractures with posterior tilt $\geq 20^\circ$ , especially among older patients.
Filipov, 2017 <sup>13</sup>	Bulgaria	Retrospective cohort study	207 patients	The cutting-edge technique known as the biplane double-supported screw fixation method (BDSF) improves the strength of the femoral neck fracture treatment by offering additional cortical support.
<b>Fixation using Alternative Implants for the Treatment of Hip fractures (FAITH) Investigators, 2017<sup>14</sup></b>	India	Retrospective cohort study	1108 patients to receive a sliding hip screw (n=557) or cancellous screws (n=551)	The sliding hip screw does not demonstrate any advantage in terms of reoperation rates; nevertheless, certain categories of patients, such as smokers and those with displaced or base of neck fractures, might fare better with a sliding hip screw than with cancellous screws.
Ran, 2014 <sup>6</sup>	Israel	Retrospective cohort study	78 patients (group 1 = 31; group 2 = 47)	The use of an internal fixation device with a set angle resulted in a reduction in both the rate of nonunion and the rate of revision. The incidence of osteonecrosis was unaffected by this factor.

Filipov, et al (2017)<sup>13</sup> showed bone union occurred in 96.6% of the cases (males 97.6%, females 96.4%, P = 0.99). Rate of nonunion was 3.4%, including fixation failure (2.4%), pseudoarthrosis (0.5%) and nonunion with AVN (0.5%). Rate of AVN was 12.1% (males 4.8%, females 13.9%, P = 0.12). Modified Harris hip score was  $86.2 \pm 18.9$  (range 10–100), with no significant difference between genders, P = 0.07. Older patients were admitted with significantly more comorbidities (P = 0.001), and on follow-up they were significantly less mobile (P = 0.005) and had significantly more difficulties to put socks and shoes on (P < 0.001).

Study by FAITH<sup>14</sup> group with 1,108 patients to receive a sliding hip screw (n=557) or cancellous screws (n=551). Reoperations within 24 months did not differ by type of surgical fixation in those included in the primary analysis: 107 (20%) of 542 patients in the sliding hip screw group versus 117 (22%) of 537 patients in the cancellous screws group (HR = 0.83, 95% CI = 0.63-1.09; p = 0.18). Avascular necrosis was more common in the sliding hip screw group than in the cancellous screws group (9% vs 5%; HR = 1.91, 1.06-3.44; p = 0.03). However, no significant difference was found between the number of medically related adverse events between groups (p = 0.82); these events included pulmonary embolism (<1% vs 1% patients; p = 0.41) and sepsis (1% vs 1%; p = 0.79).

Ran, et al (2014)<sup>6</sup> conducted a study with 78 patients (group 1 = 31; group 2 = 47) underwent reduction and internal fixation of displaced intracapsular femoral neck fractures with either Targon FN device or multiple cancellous screws from March 2000 to July 2010. One patient in group 1 (3.2%) had a nonunion, while 22 patients in group 2 (46.8%) did (P = 0.0001). Four (12.9%) patients in group 1 and sixteen (34.0%) patients in group 2 underwent revision surgery (P = 0.036). Four patients in group 1 (12.9%) and four patients in group 2 (8.5%) had osteonecrosis of the femoral head (P = 0.531). Internal fixation with the fixed-angle fixation device decreased the likelihood ratio for overall complication by a factor of 0.23, or 77% (P = 0.018).

**DISCUSSION**

Most low-energy traumas happen to older people, and they can be caused either directly or indirectly. Direct causes include falling on the greater trochanter or forcing the lower leg to turn outward, which causes the femoral neck to hit the back of the acetabulum. When muscle forces are stronger than the strength of the femoral neck, indirect processes happen.<sup>2</sup> Most femoral neck fractures in younger people are caused by high-energy injuries, like a car accident or a fall from a high place.

Athletes, new soldiers, and ballet dancers can all get stress fractures from cyclical loading. People with osteoporosis and osteopenia can get insufficiency fractures.<sup>15</sup>

Patients with displaced femoral neck fractures typically complain of groin and thigh pain and are nonambulatory, with shortening and external rotation of the lower extremity. However, patients who sustain an impacted or stress fracture of the femoral neck may lack deformity and may be able to bear weight. Patients involved in high-energy trauma should be subjected to standard Advanced Trauma Life Support (ATLS) protocols.<sup>16</sup> Pain is usually evident on attempted range of hip motion, with pain on axial compression, and with tenderness to palpation of the groin. An accurate history is important in the low-energy fracture that usually occurs in older individuals. Obtaining a history of loss of consciousness, prior syncopal episodes, medical history, chest pain, prior hip pain (pathologic fracture), and preinjury ambulatory status is important and critical in determining optimal treatment and disposition. All patients should undergo a thorough secondary survey to evaluate for associated injuries.<sup>17</sup>

Patients who have displaced fractures of the femoral neck generally complain of discomfort in the groin and the thigh and are unable to walk. Their lower extremities also tend to be shortened and rotated outwards. Patients who suffer an impacted or stress fracture of the femoral neck, on the other hand, could not have any deformity and might be able to carry their own weight. Patients who have been subjected to high-energy trauma should be treated according to the established guidelines for Advanced Trauma Life Support (ATLS).<sup>17</sup>

Pain is typically present while attempting to move the hip through its range of motion; pain is also present with axial compression; and the groin is painful to palpation. When dealing with a low-energy fracture, which most frequently affects elderly people, having an accurate medical history is essential. When establishing the best course of treatment and disposition, it is necessary and crucial to obtain a history of loss of consciousness, previous syncopal episodes, medical history, chest pain, prior hip pain, and preinjury ambulatory condition. Every patient should go through a comprehensive secondary survey to determine whether or not they have connected injuries.<sup>18</sup>

The Garden classification of femoral neck fractures is the one most commonly used in the literature. In this classification, femoral neck fractures are divided into 4 types based on the degree of displacement of the fracture fragments. A type I fracture is an incomplete or valgus-impacted fracture. A type II fracture is a complete fracture without displacement of the fracture fragments. A type III fracture is a complete fracture with partial displacement of fracture fragments. A type IV fracture is a complete fracture with total displacement of the fracture fragments, allowing the femoral head to rotate back to an anatomic position.<sup>18</sup>

In practice, however, it is difficult to differentiate the 4 types of fractures, and therefore, it may be more accurate to classify femoral neck fractures as nondisplaced (Garden I and II) or displaced (Garden III and IV). The Pauwel classification is based on the angle of fracture from the horizontal: type I: <30 degrees, type II: 30–70 degrees, and type III: >70 degrees. Increasing shear forces with increasing angle leads to more fracture instability. The OTA Classification of Femoral Neck Fractures is mainly used for research purposes. Because of poor intraobserver and interobserver reliability in using the various classifications, femoral neck fractures are commonly described as either nondisplaced or displaced. Nondisplaced fractures include impacted valgus and nondisplaced femoral neck fractures. This is a much better prognostic situation. Displaced fractures are characterized by any detectable fracture displacement.<sup>18</sup>

Osteosynthesis is the medical term for the operation in which the fracture ends are united and stabilised by means of mechanical devices such as metal plates, pins, rods, wires, or screws. This procedure is also known as "osteosynthesis." Fracture reduction and stabilisation is an essential technique, particularly after a maxillofacial injury, in order to restore patients' pre-injury form and function of facial tissues. This is especially true in cases where the patient has suffered a maxillofacial trauma.<sup>18</sup>

Over the course of the previous three decades, there has been a substantial amount of development with regard to the fixation and osteosynthesis principle. From a simple wire fixation of fracture segments, it has progressed all the way up to locking plates and screws, as well as microplates and screws built specifically for the maxillofacial region, and so on. Internal fracture fixation and external fracture fixation are the two primary categories that make up the fracture-setting system.<sup>19</sup>

Internal fixation is a type of fixation in which the mechanical devices that stabilise the fracture are placed in contact with the fractured bone and they are situated within the skin. On the other hand, external fixation is a type of fixation in which the fracture segments are fixed with metallic pins connected to an external fixator device that is placed outside the skin. This type of fixation is known as an external fixation. This chapter provides an in-depth discussion of the several subtypes of internal and external fixation techniques, as well as their underlying concepts.<sup>19</sup>

Regarding the strength of the fixation, the distal screw, which is positioned at an acute angle and supported on a vast area along the distal and posterior cortex of the femoral neck, is the most innovative and effective component of this approach. This method also follows the spiral anterior curve of the femoral neck. As a result, BDSF is able to achieve the most robust



distal and posterior cortical support that is possibly achievable for the fixation design. In addition, the medial cortical supporting points of the two calcar-buttressed screws are situated in different places from one another.<sup>13</sup>

This allows the weight-bearing load to be distributed over about fifty percent of the length of the femoral neck cortex rather than being concentrated in a single location, which reduces the risk of damage to the femoral neck. The steeper screw orientation adds to enhanced varus resistance and allows for easier screw sliding, which helps avoid cut-out and maintain stronger fixation strength. Both of these benefits are brought about by the steeper screw orientation. Furthermore, the screws' nonparallel orientation does not prevent them from moving in the femoral neck, which biomechanically represents a hollow cylinder. This is because the femoral neck is a hollow cylinder.<sup>13</sup>

Okike, et al (2019) analysis of patients with Garden-I and II femoral neck fractures, posterior tilt  $\geq 20^\circ$  was associated with a significantly increased risk of subsequent arthroplasty. Primary arthroplasty may be considered for Garden-I and II femoral neck fractures with posterior tilt  $\geq 20^\circ$ , especially among older patients.<sup>12</sup> The other factor that we found to be associated with subsequent arthroplasty was patient age  $\geq 80$  years. This is consistent with Conn and Parker's observation that age predicts fracture-healing problems. Other studies found no correlation between age and Garden-I and II femoral neck fracture reoperation.<sup>20,21</sup>

## CONCLUSION

Osteosynthesis is the medical word for joining fracture ends using metal plates, pins, rods, wires, or screws. It's called "osteosynthesis." After a maxillofacial injury, fracture reduction and stabilisation are necessary to restore facial tissues to their pre-injury state. Especially after maxillofacial trauma. Primary arthroplasty may be considered for Garden-I and II femoral neck fractures with posterior tilt  $\geq 20^\circ$ , especially among older patients.

## REFERENCES

- [1]. Chapman MW. Chapman's orthopaedic surgery. 4th ed. Boston: Lippincot Williams Wilkins; 2011.
- [2]. Morrissey N, Iliopoulos E, Osmani AW, Newman K. Neck of femur fractures in the elderly: does every hour to surgery count? *Injury*. 2017;48(6):1155–8.
- [3]. Bäcker HC, Wu CH, Maniglio M, Wittekindt S, Hardt S, Perka C. Epidemiology of proximal femoral fractures. *J Clin Orthop trauma*. 2021;12(1):161–5.
- [4]. Donnelly E, Saleh A, Unnanuntana A, Lane JM. Atypical femoral fractures: epidemiology, etiology, and patient management. *Curr Opin Support Palliat Care*. 2012;6(3):348.
- [5]. Filipov O. Epidemiology and social burden of the femoral neck fractures. *J IMAB–Annual Proceeding Sci Pap*. 2014;20(4):516–8.
- [6]. Thein R, Herman A, Kedem P, Chechik A, Shazar N. Osteosynthesis of Unstable Intracapsular Femoral Neck Fracture by Dynamic Locking Plate or Screw Fixation: Early Results. *J Orthop Trauma* [Internet]. 2014;28(2). Available from: [https://journals.lww.com/jorthotrauma/Fulltext/2014/02000/Osteosynthesis\\_of\\_Unstable\\_Intracapsular\\_Femoral.2.aspx](https://journals.lww.com/jorthotrauma/Fulltext/2014/02000/Osteosynthesis_of_Unstable_Intracapsular_Femoral.2.aspx)
- [7]. Yousrya AH, El-Beshrya SS, Benyameen GN. Fixation of unstable neck femur fractures in adults, review article. *Egypt J Hosp Med*. 2017;68(3):1374–80.
- [8]. Beale B. Orthopedic clinical techniques femur fracture repair. *Clin Tech Small Anim Pract*. 2004;19(3):134–50.
- [9]. Zacherl M, Gruber G, Glehr M, Ofner-Kopeinig P, Radl R, Greitbauer M, et al. Surgery for pathological proximal femoral fractures, excluding femoral head and neck fractures: resection vs. stabilisation. *Int Orthop*. 2011;35:1537–43.
- [10]. Sonar U V, Ingle M V, Koichade MR, Yelne AB, Malu N. Comparative study between trochanteric fixation nailing and cemented bipolar hemiarthroplasty for the treatment of unstable osteoporotic intertrochanteric neck femur fractures in elderly patients. *IOSR J Dent Med Sci*. 2014;3:31–40.
- [11]. Cuellar DO 3rd, Garcia Velez DA, Bledsoe G, Tracy Watson J. Hybrid screw fixation for femoral neck fractures: Does it prevent mechanical failure? *Injury*. 2022 Aug;53(8):2839–45.
- [12]. Okike K, Udogwu UN, Isaac M, Sprague S, Swiontkowski MF, Bhandari M, et al. Not All Garden-I and II Femoral Neck Fractures in the Elderly Should Be Fixed: Effect of Posterior Tilt on Rates of Subsequent Arthroplasty. *J Bone Joint Surg Am*. 2019 Oct;101(20):1852–9.
- [13]. Filipov O, Stoffel K, Gueorguiev B, Sommer C. Femoral neck fracture osteosynthesis by the biplane double-supported screw fixation method (BDSF) reduces the risk of fixation failure: clinical outcomes in 207 patients. *Arch Orthop Trauma Surg* [Internet]. 2017;137(6):779–88. Available from: <https://doi.org/10.1007/s00402-017-2689-8>
- [14]. Fracture fixation in the operative management of hip fractures (FAITH): an international, multicentre, randomised controlled trial. *Lancet (London, England)*. 2017 Apr;389(10078):1519–27.
- [15]. von Keudell A, Shoji K, Nasr M, Lucas R, Dolan R, Weaver MJ. Treatment options for distal femur fractures. *J Orthop Trauma*. 2016;30:S25–7.
- [16]. American College of Surgeons. Advanced Trauma Life Support (ATLS). USA; 2018.
- [17]. Rogers NB, Hartline BE, Achor TS, Kumaravel M, Gary JL, Choo AM, et al. Improving the diagnosis of ipsilateral femoral neck and shaft fractures: a new imaging protocol. *JBJS*. 2020;102(4):309–14.
- [18]. Bernstein EM, Kelsey TJ, Cochran GK, Deafenbaugh BK, Kuhn KM. Femoral neck stress fractures: an updated review. *J Am Acad Orthop Surg*. 2022;30(7):302–11.

- [19]. Davidson A, Blum S, Harats E, Kachko E, Essa A, Efraty R, et al. Neck of femur fractures treated with the femoral neck system: outcomes of one hundred and two patients and literature review. *Int Orthop*. 2022;46(9):2105–15.
- [20]. Clement ND, Green K, Murray N, Duckworth AD, McQueen MM, Court-Brown CM. Undisplaced intracapsular hip fractures in the elderly: predicting fixation failure and mortality. A prospective study of 162 patients. *J Orthop Sci Off J Japanese Orthop Assoc*. 2013 Jul;18(4):578–85.
- [21]. Conn KS, Parker MJ. Undisplaced intracapsular hip fractures: results of internal fixation in 375 patients. *Clin Orthop Relat Res*. 2004 Apr;(421):249–54.