

UTERUS PRESERVING TREATMENT MODALITIES FOR ABNORMAL INVASIVE PLACENTA: A SYSTEMATIC REVIEW

Roni Andre Syahputra Damanik *

**Faculty of Medicine, University of Jambi, Indonesia*

***Corresponding Author:**

ronidamanikandre@gmail.com

Abstract

All medical personnel who provide care for pregnant women face a challenge in diagnosing and treating abnormal placentation since it displays a unique set of symptoms. The direct attachment of placental villi to the myometrium, with the risk of further invasion into the uterine wall or surrounding organs, is one of the leading causes of postpartum hemorrhage. Aberrant placentation is defined by this direct attachment of placental villi to the myometrium. It has been determined that primary risk factors for placenta accreta include surgical procedures that damage uterine integrity. These operations include cesarean section, dilatation and curettage, and myomectomy. When a focal accreta is identified, conservative treatments, such as preserving the uterus and placenta and then undergoing methotrexate therapy or pelvic artery embolization, may be explored. Despite this, surgical management is still the gold standard for treating the condition. Due to the intricacy of surgery, conservative management should be reserved for individuals who are interested in preserving their fertility as well as those who have major disease.

Keyword: *Abnormal Invasive Placenta; Conservative Management; Surgery; Uterus Preserving Treatment*

INTRODUCTION

Abnormal placentation presents a diagnostic and therapeutic challenge for all medical professionals who care for pregnant women. As one of the primary causes of postpartum bleeding, aberrant placentation is characterized by the direct attachment of placental villi to the myometrium, with the possibility for deeper invasion into the uterine wall or neighboring organs. Surgical procedures that compromise uterine integrity, including as cesarean section, dilatation and curettage, and myomectomy, have been identified as major risk factors for placenta accreta.¹

Placenta previa following a previous cesarean delivery/section is the most important risk factor for the development of a PAS. The difficulty in diagnosing this illness explains why the frequency of placenta accreta varies between 1 in 300 and 1 in 2000 pregnancies.^{2,3} The presence of placenta previa is connected with a 3% risk of PAS among women who have had a prior single cesarean birth, while the lack of placenta previa is associated with a 0.03% risk of PAS.⁴

According to Jauniaux et al latest's meta-analysis, the prevalence of PAS ranges between 0.01% and 1%. This risk difference is significantly more severe among female patients who have undergone more than one cesarean section. Women who were older than 35 years old and who had a personal history of pelvic irradiation, manual placenta removal, endometritis, or infertility had a higher chance of developing PAS compared to control groups.⁵

Typically, gray-scale ultrasound is used to make the diagnosis, which is then confirmed by magnetic resonance imaging, which may better clarify the degree of placental invasion.⁶ Preoperative planning can greatly reduce blood loss and prevent major morbidity associated with placenta accreta. Thus, it is crucial to make the diagnosis before delivery. For these individuals, aggressive care of hemorrhage with uterotonics, fluid resuscitation, blood products, scheduled hysterectomy, and surgical hemostatic medications can save their lives.^{7,8}

When a focal accreta is suspected, conservative intervention, including uterine and placental preservation and subsequent methotrexate therapy or pelvic artery embolization, may be considered; nonetheless, surgical management remains the standard of care.^{7,8} Recent studies have showed an interest in preserving the uterus and avoiding hysterectomy by leaving a portion or the entire adherent placenta in the uterus, so preserving fertility and maybe reducing problems.

The goal of this research project is to discover different therapeutic options that will preserve the uterus in cases with aberrant invasive placenta.

METHODS

Protocol

The author made sure that this research met the standards by using the Preferred Reporting Items for Systematic Review and Meta-Analysis (PRISMA) 2020 guidelines. This is done to make sure that the investigation's findings are correct.

Criteria for Eligibility

This literature review examines uterus-preserving therapy options for atypical invasive placenta. This is accomplished by assessing or studying previous research on the topic. The purpose of this essay is to demonstrate the significance of the discussed difficulties. Researchers who participated in research satisfied the following criteria: 1) In order for the manuscript to be accepted for publication, it must be written in English and focus on protecting the uterus through aberrant invasive placenta therapy approaches. 2) This review contains articles published after 2017 but prior to the time frame this systematic review examines. Research that is not permitted includes editorials, submissions without a DOI, already published review articles, and entries that are almost identical to previously published journal papers.

Search Strategy

We used "uterus preserving treatment" and "abnormal invasive placenta" as keywords. The search for studies to be included in the systematic review was carried out from February, 20th 2023 using the PubMed and SagePub databases by inputting the words: ("uterus"[MeSH Terms] OR "uterus"[All Fields] OR "uteri"[All Fields]) AND ("preservation, biological"[MeSH Terms] OR ("preservation"[All Fields] AND "biological"[All Fields]) OR "biological preservation"[All Fields] OR "preservation"[All Fields] OR "preserved"[All Fields] OR "preservations"[All Fields] OR "preserve"[All Fields] OR "preserves"[All Fields] OR "preserving"[All Fields]) AND ("therapeutics"[MeSH Terms] OR "therapeutics"[All Fields] OR "treatments"[All Fields] OR "therapy"[MeSH Subheading] OR "therapy"[All Fields] OR "treatment"[All Fields] OR "treatment s"[All Fields]) AND ("abnormal"[All Fields] OR "abnormalities"[MeSH Subheading] OR "abnormalities"[All Fields] OR "congenital abnormalities"[MeSH Terms] OR ("congenital"[All Fields] AND "abnormalities"[All Fields]) OR "congenital abnormalities"[All Fields] OR "abnormality"[All Fields] OR "abnormally"[All Fields] OR "abnormals"[All Fields] OR "abnormities"[All Fields] OR "abnormity"[All Fields]) AND ("invasibility"[All Fields] OR "invasible"[All Fields] OR "invasion"[All Fields] OR "invasions"[All Fields] OR "invasive"[All Fields] OR "invasively"[All Fields] OR "invasiveness"[All Fields] OR "invasives"[All Fields] OR "invasivity"[All Fields]) AND ("placenta"[MeSH Terms] OR "placenta"[All Fields] OR "placentas"[All Fields] OR "placenta s"[All Fields] OR "placentae"[All Fields]) used in searching the literature.

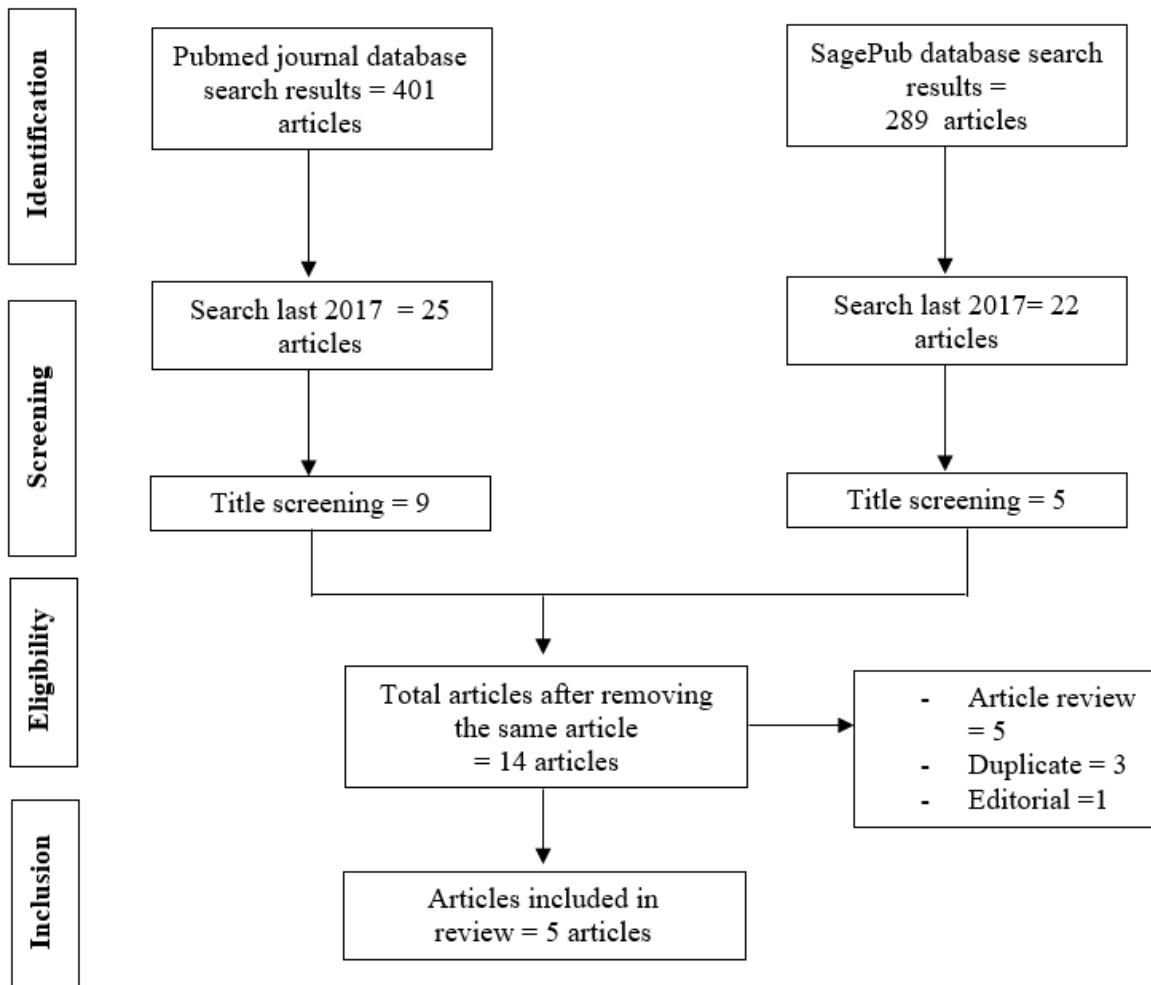


Figure 1. Article search flowchart

Data retrieval

The authors examined each study after reading the abstract and title to see if it met the inclusion criteria. The authors then chose various studies from the past to use as sources in this article. This conclusion was reached after reviewing numerous studies that all revealed the same pattern. All entries must be written in English and never before published.

In the systematic review, only studies that met all of the inclusion criteria were considered. This narrows the search results to only those that are relevant. We do not consider research findings that do not meet our criteria. Following this, the research will be thoroughly examined. During the course of this study's investigation, the following information was discovered: names, authors, dates of publication, location, study activities, and parameters.

Quality Assessment and Data Synthesis

Before deciding which papers to investigate further, each author conducted their own research on the research listed in the publication's title and abstract. Then, we'll look at all papers that meet the review's inclusion criteria and are thus good enough to be included. Then, based on our findings, we'll choose which papers to include in the review. This criterion is used to select manuscripts for evaluation. To make selecting papers to review as simple as possible. Which previous studies were conducted, and what aspects of those studies qualified them for inclusion in the review?

RESULT

First study showed inflated Cook Cervical Ripening Balloon (ICRB) was linked with a reduction in surgical time and duration of infrarenal abdominal aorta balloon occlusion (IAABO) (mean 172.7 min vs 206.6 min, p = 0.017; median 30 min vs 40 min, p 0.001), and significantly decreased the rate of peripartum hysterectomy (2.9% vs 30.4%, p = 0.001). Use of ICRB significantly decreased the estimated amount of blood loss (median 2500 ml vs 4000 ml, p 0.001), the amounts of packed red blood cells and fresh-frozen plasma transfusion (median 6 U vs 13.5 U, p 0.001; median 450 ml vs 1200 ml, p 0.001), the postoperative hospital stay and the incidence of oligomenorrhea Regarding the use of cryo and PLT, injury to the urinary system, relaparotomy, admission to the ICU, postpartum hematocoele in the uterine cavity, and postoperative complications, there was no significant difference between the two groups (including incidence rate of DVT, incidence rate of femoral thrombosis, puerperal morbidity, intrauterine infection, surgical site infection, and deep tissue infection).⁹

Kilicci, et al (2018)¹⁰ study conducted study with 51 pregnant women satisfied the criteria for participation in the study. In 29 patients, a cesarean hysterectomy was performed, and segmental resection was done in 22 individuals. Both the major problems that occurred during the operation and those that occurred after were comparable between the two groups. There were statistically significant differences ($p < 0.05$) between the groups in terms of gravidity, pre- and post-operative hemoglobin concentrations, the number of packed red blood cell transfusions, and the amount of time spent operating.

Table 1. The literature include in this study

Author	Origin	Method	Sample Size	Result
Yongzhong, 2022 ⁹	China	Retrospective cohort study	74 patients suffering with previa PAS	ICRB was a straightforward, effective technique for postpartum hemorrhage (PPH) management and fertility preservation in some previa PAS cases in which abnormally invasive placenta reached the cervical internal ostium and upper cervical canal, in conjunction with IAABO and compression suture.
Kilicci, 2018 ¹⁰	Turkey	Single-center retrospective study	29 patients and segmental resection in 22	Patients who have severe invasive placentation have the option of undergoing an initial fertility conserving surgical surgery rather than having a cesarean hysterectomy performed. This treatment requires less blood transfusions and a shorter amount of time for the operation.
Babaei, 2019 ¹¹	Iran	Case series	Twenty-six patients were identified who had the diagnosis of abnormal placenta implantation	In spite of the fact that this surgical procedure has a high rate of success when it comes to preserving the uterus, there is still a chance that the therapy may be unsuccessful. This method should be reserved for patients who have a strong desire to maintain the uterus and their fertility, or if it is technically difficult to perform hysterectomy due to the extent of the invasion. Because there are too few data regarding its efficacy and safety, this method should be reserved for patients who have a strong desire to maintain the uterus and their fertility.
Varlas, 2021 ¹²	Romania	Retrospective analysis	12 patients	In cases when fertility is desired or where significant illness makes surgery problematic, conservative care is the approach that should be used. The earlier risk factors are identified and managed strategically, the more likely it is that maternal and fetal outcomes will be improved.
Gulucu, 2022 ¹³	Turkey	Retrospective analysis	35 patients who underwent PPH	It is recommended that medicinal and surgical procedures be used to attempt to maintain the uterine cavity prior to PPH; nevertheless, in the event that this is not successful, a hysterectomy is the final life-saving option. PPH may be necessary in individuals who have anemia and increased gravidity since the risk of bleeding is likely to be considerable in the first twenty-four hours after delivery in such patients, and it is important to remember this fact.

Babaei, et al (2019)¹¹ showed abnormal placenta implantation diagnosis was determined to be present in twenty-six different cases. Since they had their condition treated through caesarean hysterectomy, fourteen individuals were not included in the study. Seven out of the other 12 patients had their uteri preserved without any complications, representing 58% of the total. All of the women who were effectively treated began having regular menstrual periods again, even though they had no interest in becoming pregnant. In five patients, a primary or delayed hysterectomy was performed

because of severe post-partum hemorrhage in three of the cases, intestinal adhesion/peritonitis in two of the patients, and secondary post-partum hemorrhage/sepsis in one patient. This accounts for 42 percent of the total number of patients.

Varlas, et al (2021)¹² conducted a study with 12 patients. One instance was treated conservatively at 37 weeks gestation, and the prognosis for the mother was uterine preservation. All of the women had risk indicators for an unusually invasive placenta, such as placenta previa or a prior cesarean birth. The majority of women had scheduled cesarean deliveries at a mean gestational age of 36.40.9 weeks. In our analysis, the uterus was saved in just one case (8.33%), whereas the remaining patients had hysterectomy with preservation of the ovaries. The average maternal blood loss during operation was 2,1751,450 milliliters. Only one instance (8.33%) had severe maternal consequences. We discovered a low rate of uterine preservation and a favorable perinatal outcome.

Gulucu, et al (2022)¹³ showed PPH was performed in 35 (3.2/1000) patients who gave birth during the study period. The most prevalent rationale for hysterectomy was placental invasion abnormality (57.1%, n = 20), and complete hysterectomy was the most often done procedure (68.6%, n = 24). The most frequent alternative treatment done prior to hysterectomy was bilateral hypogastric artery ligation (14.3%, n = 5), and the most common consequence was bladder damage (22.9%, n = 8). Due to acute blood loss, blood transfusions were conducted on 94.3% (n = 33) of the patients. The mean newborn weight was 2788.79 ± 913.37 g, and the 1st and 5th-minute APGAR scores were 6.71 ± 2.25 and 7.56 ± 2.35, respectively.

DISCUSSION

Placenta praevia is a disorder in which the placenta is abnormally positioned close to or above the internal cervical opening (ICO). Abnormal placental attachment (placenta accreta, increta, percreta) is a spectrum condition ranging from improper adhesion to placental tissue that is profoundly invasive.³ Individualization is the best treatment for placenta sticky problems as the optimal technique is debatable. These situations require a multidisciplinary approach from gynaecologists, interventional radiologists, and general surgeons. Expert clinical pharmacists and other professionals can also reduce pharmaceutical adverse effects.

As the best strategy for the management of placenta adhesive disorders is controversial, individualisation in any case remains the best treatment policy. Furthermore, a multidisciplinary approach including the gynaecologist, interventional radiologist, and general surgeon, is needed in order to manage these cases. In addition, the presence of an expert clinical pharmacist along with other specialists will be very helpful in minimising the side effects of the medications.

Even though the procedure has some risks of severe bleeding and some other difficulties due to morbidly adherent placenta to the adjacent structures, clinicians choose to perform cesarean hysterectomy in the majority of cases with abnormal placentation. This is despite the fact that the procedure has some difficulties to perform and some risks of severe bleeding. In addition, it is possible that it is not a good solution for younger women who want to keep their fertility and keep their uterus intact.¹⁴

As a result, several conservative options have been suggested in the published research. These include the following: leaving the placenta completely or partially in situ with or without selective arterial embolization; the cervical inversion technique; the stepwise cesarean section technique; or the Triple P procedure. These are just a few of the procedures that have been suggested as conservative options by various authors.^{15,16}

Arterial embolisation is an effective method of treating postpartum hemorrhage. A patient with stable vital signs and continuous bleeding, particularly if the loss rate is not severe, may be a candidate for arterial embolisation. In this analysis, the success rate was 89.8%. Although the operation has the potential to preserve fertility, it is confined to centres with a high level of skill because to the necessity for specialized equipment and the urgency of continued postpartum hemorrhage. The use of preventive embolisation in combination with a scheduled caesarean section for AIP may be beneficial.¹⁷

As proximal as the aorta and as distal as the anterior division of the internal iliac arteries, occlusion balloons have been placed at various locations. This procedure has frequently been coupled with concurrent arterial embolisation. The bulk of published research are severely constrained by tiny sample sizes. Very rarer are studies investigating the exclusive use of occlusion balloons to limit hemorrhage in AIP patients. Recent reports of occlusion balloon implantation in the aorta common iliac arteries, the internal iliac arteries, and the uterine arteries show that this approach may be effective for intraoperative management.¹⁸

After the delivery of the baby, one of the more traditional methods consisted of just leaving the placenta where it was. This management strategy has been the subject of case reports and case series that have been published. One of these case series claimed an 84% rate of uterine preservation by using this method. It was also found that there was a decreased incidence of complications. On the other hand, there was a lack of information on the contrast between this method and the hysterectomy performed by cesarean section.¹⁹⁻²¹

Babaei et al. (2019)¹¹ carried out one of the most extensive case series in order to evaluate the efficacy and safety of combining UAE and MTX in the treatment of placental sticky diseases. The current study found that 58% of women were able to have their uteruses successfully preserved, but 42% of women had some kind of maternal morbidity. Many case

reports and case series evaluated the effectiveness and safety of the combination of UAE and MTX in the treatment of clinicleathological or radiologically aberrant placenta implantation.²²

The activity of MTX against rapidly dividing cells is the primary mechanism that contributes to its effectiveness against proliferating trophoblast. Because of this, the administration of MTX is considered to be one of the primary therapy options, not only for the treatment of ectopic pregnancy but also for the treatment of prenatal trophoblastic illness. There have been a number of publications that cast doubt on the benefits of using MTX as part of a more conservative treatment plan for atypical sticky placenta.^{11,23}

It is recommended that medicinal and surgical procedures be used to attempt to maintain the uterine cavity prior to PPH; nevertheless, in the event that this is not successful, a hysterectomy is the final life-saving option. PPH may be necessary in individuals who have anemia and increased gravidity since the risk of bleeding is likely to be considerable in the first twenty-four hours after delivery in such patients, and it is important to remember this fact. Because there is a risk of complications, the need for greater blood transfusions, and the demand for intensive care, patients who have placentation defects should preferably have their surgeries performed in centers that have prior expertise.¹³

CONCLUSION

Conservative care should be reserved for patients desiring fertility and those with significant illness due to the complexity of surgery.

REFERENCE

- [1]. Guleria K, Gupta B, Agarwal S, Suneja A, Vaid N, Jain S. Abnormally invasive placenta: changing trends in diagnosis and management. *Acta Obstet Gynecol Scand*. 2013;92(4):461–4.
- [2]. Jauniaux ERM, Alfirevic Z, Bhide AG, Belfort MA, Burton GJ, Collins SL, et al. Placenta praevia and placenta accreta: diagnosis and management: green-top guideline no. 27a. *Bjog*. 2018;126(1):e1–48.
- [3]. Leanza V, Verzi MG, Genovese F, Colaleo FM, Leanza G, Palumbo M. Central placenta praevia accreta with focal bladder percreta. Conservative management. *Ann Ital Chir*. 2021 May;10.
- [4]. Jauniaux E, Bunce C, Grønbeck L, Langhoff-Roos J. Prevalence and main outcomes of placenta accreta spectrum: a systematic review and meta-analysis. *Am J Obstet Gynecol*. 2019;221(3):208–18.
- [5]. Jauniaux E, Bhide A, Kennedy A, Woodward P, Hubinont C, Collins S. FIGO consensus guidelines on placenta accreta spectrum disorders: Prenatal diagnosis and screening. *Int J Gynaecol Obstet Off organ Int Fed Gynaecol Obstet*. 2018 Mar;140(3):274–80.
- [6]. Collins SL, Ashcroft A, Braun T, Calda P, Langhoff-Roos J, Morel O, et al. Proposal for standardized ultrasound descriptors of abnormally invasive placenta (AIP). Vol. 47, *Ultrasound in Obstetrics & Gynecology*. John Wiley & Sons, Ltd Chichester, UK; 2016. p. 271–5.
- [7]. Bauer ST, Bonanno C. Abnormal placentation. *Semin Perinatol*. 2009 Apr;33(2):88–96.
- [8]. Baughman WC, Corteville JE, Shah RR. Placenta Accreta: Spectrum of US and MR Imaging Findings. *RadioGraphics [Internet]*. 2008 Nov 1;28(7):1905–16. Available from: <https://doi.org/10.1148/rg.287085060>
- [9]. Gu Y, Zhou Y, Li L, Li H, Wang S, Wang Y, et al. Cook Cervical Ripening Balloon for placenta accreta spectrum disorders with placenta previa: a novel approach to uterus preserving. *Arch Gynecol Obstet*. 2022 Dec;306(6):1979–87.
- [10]. Kilicci C, Ozkaya E, Eser A, Bostanci EE, Sanverdi I, Abide Yayla C, et al. Planned cesarean hysterectomy versus modified form of segmental resection in patients with placenta percreta. *J Matern neonatal Med Off J Eur Assoc Perinat Med Fed Asia Ocean Perinat Soc Int Soc Perinat Obstet*. 2018 Nov;31(22):2935–40.
- [11]. Babaei MR, Oveysi Kian M, Naderi Z, Khodaverdi S, Raoofi Z, Javanmanesh F, et al. Methotrexate infusion followed by uterine artery embolisation for the management of placental adhesive disorders: a case series. *Clin Radiol*. 2019 May;74(5):378–83.
- [12]. Varlas VN, Bors RG, Birsanu S, Maxim B, Clotea E, Mihailov M. Maternal and fetal outcome in placenta accreta spectrum (PAS) associated with placenta previa: a retrospective analysis from a tertiary center. *J Med Life*. 2021;14(3):367–75.
- [13]. Gulucu S, Uzun KE, Ozsoy AZ, Delibasi IB. Retrospective evaluation of peripartum hysterectomy patients: 8 years' experience of tertiary health care. *Niger J Clin Pract*. 2022 Apr;25(4):483–9.
- [14]. Warshak CR, Eskander R, Hull AD, Scioscia AL, Mattrey RF, Benirschke K, et al. Accuracy of ultrasonography and magnetic resonance imaging in the diagnosis of placenta accreta. *Obstet Gynecol*. 2006;108(3 Part 1):573–81.
- [15]. Eller AG, Porter TF, Soisson P, Silver RM. Optimal management strategies for placenta accreta. *BJOG An Int J Obstet Gynaecol*. 2009;116(5):648–54.
- [16]. Comstock CH. Antenatal diagnosis of placenta accreta: a review. *Ultrasound Obstet Gynecol Off J Int Soc Ultrasound Obstet Gynecol*. 2005;26(1):89–96.
- [17]. Steins Bisschop CN, Schaap TP, Vogelvang TE, Scholten PC. Invasive placentation and uterus preserving treatment modalities: a systematic review. *Arch Gynecol Obstet*. 2011;284:491–502.
- [18]. Panici PB, Anceschi M, Borgia ML, Bresadola L, Masselli G, Parasassi T, et al. Intraoperative aorta balloon occlusion: fertility preservation in patients with placenta previa accreta/increta. *J Matern Neonatal Med*. 2012;25(12):2512–6.
- [19]. Timmermans S, van Hof AC, Duvekot JJ. Conservative management of abnormally invasive placentation. *Obstet*

- Gynecol Surv. 2007;62(8):529–39.
- [20]. Kayem G, Davy C, Goffinet F, Thomas C, Clément D, Cabrol D. Conservative versus extirpative management in cases of placenta accreta. *Obstet Gynecol.* 2004;104(3):531–6.
- [21]. Bretelle F, Courbière B, Mazouni C, Agostini A, Cravello L, Boubli L, et al. Management of placenta accreta: morbidity and outcome. *Eur J Obstet Gynecol Reprod Biol.* 2007;133(1):34–9.
- [22]. Dinkel H-P, Dürig P, Schnatterbeck P, Triller J. Percutaneous treatment of placenta percreta using coil embolization. *J Endovasc Ther.* 2003;10(1):158–62.
- [23]. Committee opinion no. 529: placenta accreta. *Obstet Gynecol.* 2012 Jul;120(1):207–11.