

# BONE MARROW ASPIRATE CONCENTRATE FOR THE TREATMENT OF OSTEOCHONDRAL LESIONS OF THE TALUS: A SYSTEMATIC REVIEW OF OUTCOMES

Indra Gunawan\*

\*Faculty of Medicine, University of Jambi, Indonesia

\*Corresponding Author:  
[indrakabhuom@gmail.com](mailto:indrakabhuom@gmail.com)

---

## Abstract

Monro, who removed a loose body from the ankle produced by traumatic injury, most likely provided the first description of an ankle OCL. Monro was the first person to describe an ankle OCL. The most important thing that was discovered as a result of this investigation was that there was a dearth of information in the published literature concerning the use of BMAC for the treatment of OLTs with very different indications, associated procedures, and outcome evaluations. This was the finding that stood out the most. This was the most important finding that came out of the research. On the other hand, the clinical trials that were examined indicated a variety of positive outcomes for the treatment of modestly sized chondral lesions, and there were no major difficulties noted in any of the studies. Only one of the studies that were included in this analysis was prospective and made use of a control group. This is despite the fact that all three of the studies that were included in this review had a quality that varied from moderate to high, as judged by the mCMS. According to the findings of this investigation, there is an alarming lack of long-term data and high-level evidence to support the deployment of this treatment approach. These two types of evidence are needed to lend support for the utilization of this therapeutic strategy. In spite of this, the evidence that was readily available revealed that BMAC was helpful for the treatment of ankle cartilage anomalies, albeit with varying degrees of success. This was the case despite the fact that there was no cure for the condition.

**Keyword:** Bone Marrow Concentrate; Mesenchymal Stem Cells; Osteochondral Lesions; Talus

**INTRODUCTION**

Osteochondral lesions of the talus, also known as OLTs, are becoming easier to diagnose and treat as a result of advancements in imaging technology that continue to make it possible to detect cartilage defects in a greater number of patients. According to some statistics, up to half of all cases of acute ankle sprains and fractures may be connected with other types of ankle injuries. Increases in pain and stiffness are typical signs of OLTs, as are functional constraints such as reduced activity levels.<sup>1-4</sup>

There is a possibility that biological adjuncts like bone marrow aspirate concentrate (BMAC), for example, could be beneficial in prolonging the effects of cartilage repair treatments performed on the talus. The aspirate that is taken from bone marrow contains both mesenchymal stem cells (also known as MSCs) and hematopoietic stem cells. It has been hypothesized that a concentrate of bone marrow aspirate can help in the process of tissue regeneration, hence improving the caliber of cartilage repair through an increase in aggrecan content and tissue hardness.<sup>3,5</sup>

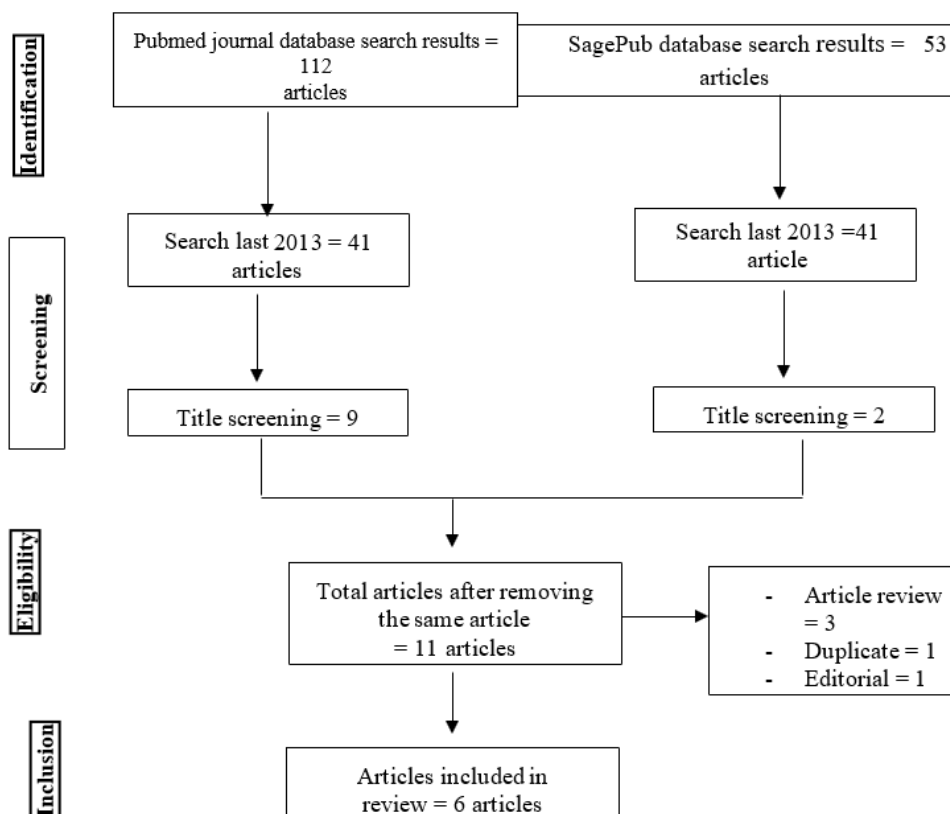
As a consequence of this, BMAC contributes to the maintenance of a potentially healthy environment for the growth and repair of hyaline cartilage, while simultaneously reducing the production of fibrocartilage. These ideas have recently been tested in animal models, where they have initially demonstrated encouraging outcomes and a manageable risk profile with relation to BMAC. When bone marrow stimulation (BMS) approaches were used with BMAC, the results were much more beneficial to cartilage healing than when BMS was used alone.<sup>3-6</sup>

In particular, the cartilage defects that had been present repaired with a greater amount of hyaline cartilage (collagen type II), an increased amount of glycosaminoglycan, and an improved overall histological organization.<sup>5,7</sup> As a consequence of these findings, BMAC is currently being researched as a potential treatment for OLTs in human patients. In addition, BMAC is now one of the few techniques of delivering stem cells intraoperatively that has been approved by the Food and Drug Administration (FDA) of the United States of America.<sup>8-10</sup>

When it comes to indications, timing, and results, the total body of evidence supporting the use of BMAC for the treatment of chondral disorders is scant and very variable. On the other hand, the results of using BMAC for the treatment of OLTs have been published in the past.<sup>9,11,12</sup> This article was conceived with the intention of investigating the results obtained by patients who were treated with bone marrow aspirate concentrate for osteochondral lesions of the talus.

**METHODS PROTOCOL**

This investigation was conducted in accordance with the Preferred Reporting Items for Systematic Review and Meta-Analysis (PRISMA) 2020 recommendations. This measure was taken to ensure that the study's findings are accurate and trustworthy.



**Figure 1.** Article search flowchart

### Search Strategy

We use “bone marrow aspirate concentrate”; “osteochondral lesions” and “outcome”. The search for studies to be included in the systematic review was carried out from February, 15<sup>th</sup> 2023 using the PubMed and SagePub databases by inputting the words: ("bone marrow"[MeSH Terms] OR ("bone"[All Fields] AND "marrow"[All Fields]) OR "bone marrow"[All Fields]) AND ("aspirant"[All Fields] OR "aspirants"[All Fields] OR "aspirate"[All Fields] OR "aspirated"[All Fields] OR "aspirates"[All Fields] OR "aspirating"[All Fields] OR "aspiration"[All Fields] OR "aspirational"[All Fields] OR "aspirations, psychological"[MeSH Terms] OR ("aspirations"[All Fields] AND "psychological"[All Fields]) OR "psychological aspirations"[All Fields] OR "aspirations"[All Fields] OR "aspirative"[All Fields] OR "aspirator"[All Fields] OR "aspirators"[All Fields] OR "aspire"[All Fields] OR "aspired"[All Fields] OR "aspires"[All Fields] OR "aspiring"[All Fields]) AND ("concentrate"[All Fields] OR "concentrated"[All Fields] OR "concentrates"[All Fields] OR "concentrating"[All Fields] OR "concentration"[All Fields] OR "concentrations"[All Fields]) AND ("osteochondral"[All Fields] OR "osteochondritis"[MeSH Terms] OR "osteochondritis"[All Fields] OR "osteochondritides"[All Fields]) AND ("lesion"[All Fields] OR "lesion s"[All Fields] OR "lesional"[All Fields] OR "lesions"[All Fields]) AND ("outcome"[All Fields] OR "outcomes"[All Fields]) is used as search keywords.

### Criteria for Eligibility

The goal of this literature review is to investigate and analyze the findings of previous studies on the outcomes of patients treated with bone marrow aspirate concentrate for talus osteochondral lesions. The ongoing investigation has revealed a significant issue that must be addressed. Participants in research projects must meet one or more of the following requirements: 1) To be considered for publication, papers must be written in English and discuss the outcomes of patients treated with bone marrow aspirate concentrate for osteochondral lesions of the talus. 2) This analysis includes articles published after 2018, but before the time period under consideration in this systematic review. Editorials, submissions without a DOI, previously published review articles, and entries that are essentially identical to those that have already been published in a journal are some examples.

### Data retrieval

After reviewing the titles and abstracts of a number of other research, the author decided to alter the criteria for inclusion. The additional resources for the research include specifics regarding the newly developed criteria. This highlighted how significant and intricate the issue is, indicating that additional research into the matter is required. Examining a lot of research that were all organized in the same way led to the discovery of this conclusion.

In systematic reviews, the papers that are considered are limited to only those that satisfy all of the inclusion criteria. This made it much simpler to zero in on the specific items that were of significance. Our research team did not accept the study suggestions because they did not satisfy the standards that we had established. As a result, it was certain that the probe would be finished. During the course of this inquiry, we discovered many items including names, authors, publication dates, locations, study activities, and parameters.

### Quality Assessment and Data Synthesis

Each author independently reviewed a research study that was offered in the titles and abstracts of the papers before making a decision regarding which articles to analyze. Following that, we will look at all of the papers that have the potential to be included in a systematic review. The articles that will be evaluated will be chosen on the basis of the findings that we make. This is how the writing that will be reviewed was selected in the first place. Contribute to making it simpler to assess various articles. Which previous studies can be incorporated into the review, and how may this be done?

### RESULT

Vannini, et al (2021) studu showed AOFAS score increased from  $52.3 \pm 14.3$  to  $73.5 \pm 23.1$  ( $p < 0.05$ ), although the AOS pain and disability subscales fell from  $70.9 \pm 14.1$  to  $37.2 \pm 32.7$  and from  $69.0 \pm 14.8$  to  $34.2 \pm 29.3$ , respectively (both  $p < 0.05$ ). The satisfaction percentage was  $61.8 \pm 41.2\%$ , and 68.6% of patients would undertake the surgical operation again. There were 17 documented failures, with a failure rate of 33.3%. Those affected by grade 3 OA had a high failure rate of 71.4%, as did older patients and those whose cases were more complex and required previous or combination procedures.

Hannon, et al (2016)<sup>13</sup> showed mean FAOS and SF-12 PCS scores increased significantly from pre- to post-operatively ( $P < 0.01$ ) at 48.3 months (range, 34-82 months) for the cBMA/BMS group and 77.3 months (range, 46-100 months) for the BMS-alone group. The cBMA/BMS group scored considerably higher on the MOCART than the BMS group ( $P = 0.023$ ). In cBMA/BMS patients, the superficial and deep T2 relaxation values were greater in repair tissue than in neighboring natural articular cartilage ( $P = 0.030$  and  $P < 0.001$ , respectively).

**Table 1.** The literature include in this study.

Author	Origin	Method	Sample Size	Result
Vannini, 2021 <sup>14</sup>	Italy	Prospective study	56 consecutive patients	At 10 years, the AOFAS score increased from 52.3 ± 14.3 to 73.5 ± 23.1 (p <0.05), although the AOS pain and disability subscales fell from 70.9 ± 14.1 to 37.2 ± 32.7 and from 69.0 ± 14.8 to 34.2 ± 29.3, respectively (both p <0.05). The satisfaction percentage was 61.8 ± 41.2%, and 68.6% of patients would undertake the surgical operation again.
Hannon, 2016 <sup>13</sup>	United State of America	Case-Control Study	Twenty-two patients	Mean FAOS and SF-12 PCS scores increased significantly from pre- to post-operatively (P <0.01) at 48.3 months (range, 34-82 months) for the cBMA/BMS group and 77.3 months (range, 46- 100 months) for the BMS-alone group. The cBMA/BMS group scored considerably higher on the MOCART than the BMS group (P = 0.023). In cBMA/BMS patients, the superficial and deep T2 relaxation values were greater in repair tissue than in neighboring natural articular cartilage (P = 0.030 and P <0.001, respectively).
Giannini, 2013 <sup>8</sup>	Italy	Case series	Forty-nine patients	The overall AOFAS score improved from 63.73 ± 14.13 preoperatively to 82.19 ± 17.04 at 48 ± 6.1 months (P <0.01), with best results at the 24-month follow-up. A significant decrease in the clinical score was observed between 24 and 36 months postoperatively (P = 0.001) and between 24 and 48 months (P <0.01). The T2-mapping analysis showed regenerated tissue with T2 values of 35 to 45 milliseconds, similar to hyaline cartilage, in a mean of 78% ± 16% of the repaired lesion area.
Kim, 2022 <sup>15</sup>	Republic of Korea	Prospective study	Forty-five patients	Forty-five patients were included and mean follow-up was 39.1 months (range, 13-97 months). Mean lesion size and depth were 180.7 ± 110.4 mm <sup>2</sup> and 9.6 ± 3.7 mm, respectively. BMIC was performed without malleolar osteotomy in 36 patients (80%) and bone graft was performed in 42 (93.3%). VAS, FFI, and FAOS improved significantly. No complication occurred and no revision was required.
Murphy, 2019 <sup>16</sup>	Ireland	Prospective cohort study	101 patients	There were 101 participants in the study. 52 patients were assigned to the microfracture group and 49 to the microfracture/BMAC group. Both groups were followed for a minimum of 36 months. Both groups experienced statistically significant improvements in pain scores, quality of life scores, sport participation, and daily activities. The revision rate was statistically significant, p=0.0145, at 28.8% in the microfracture group and 12.2% in the microfracture/BMAC group. In both cohorts, the majority of lesions were smaller than 1.5 cm <sup>2</sup> in size.
Davila, 2021 <sup>17</sup>	USA	Retrospective cohort study	14 patients	All patients regained full extension; however, 1 patient later acquired a 2° extension contracture after a traumatic event. The average hamstring strength significantly increased from 4.1 to 4.6 postoperatively (p = 0.33). The average quadriceps strength significantly increased from 4.0 to 4.5 postoperatively (p = 0.007). Mean visual analog scale scores significantly decreased postoperatively (4.5 vs 1.4; p = 0.001). There was a significant increase in Knee Outcome Survey Activities of Daily Living scores (53.8 vs 92.9; p = 0.007). Mean Knee Outcome Survey-Sports scores also increased, although this was nonsignificant (28.2 vs 79.5; p = 0.560).

Other study showed AOFAS score improved from 63.73 ± 14.13 preoperatively to 82.19 ± 17.04 at 48 ± 6.1 months (P <0.01), with best results at the 24-month followup. A significant decrease in the clinical score was observed between 24 and 36 months postoperatively (P = 0.001) and between 24 and 48 months (P <0.01). The T2-mapping analysis showed regenerated tissue with T2 values of 35 to 45 milliseconds, similar to hyaline cartilage, in a mean of 78% ± 16% of the repaired lesion area.<sup>8</sup>

The time between the occurrence of trauma and surgery was found to negatively affect the clinical outcome at the latest follow-up; patient’s age and lesion size influenced the early clinical results but did not affect the outcome at final follow-up. The stability of clinical results over time and the percentage of tissue with values similar to hyaline cartilage evidenced by MRI T2 mapping showed a tendency to correlate at the last followup (r = 0.497, P = 0.06).<sup>8</sup>

Other study conducted with forty-five patients were included and mean follow-up was 39.1 months (range, 13-97 months). Mean lesion size and depth were 180.7 ± 110.4 mm<sup>2</sup> and 9.6 ± 3.7 mm, respectively. BMIC was performed without malleolar osteotomy in 36 patients (80%) and bone graft was performed in 42 (93.3%). VAS, FFI, and FAOS improved significantly. No complication occurred and no revision was required.<sup>15</sup>

Murphy, et al (2019)<sup>16</sup> conducted a study with 101 participants. 52 patients were assigned to the microfracture group and 49 to the microfracture/BMAC group. Both groups were followed for a minimum of 36 months. Both groups experienced statistically significant improvements in pain scores, quality of life scores, sport participation, and daily activities. The revision rate was statistically significant, p=0.0145, at 28.8% in the microfracture group and 12.2% in the microfracture/BMAC group. In both cohorts, the majority of lesions were smaller than 1.5cm<sup>2</sup> in size.

A retrospective chart review was performed for patients treated arthroscopically with BMAC and CDM between August 2015 and August 2018 and had more than 1-year follow-up. According to the findings of Davila's (2021) study, there were no significant changes seen in pain or functional results when the osteochondral defect size and position were taken into consideration. Among the complications that occurred were a stitch abscess, a Baker's cyst, and lingering pain that was managed with an injection of hyaluronic acid.<sup>17</sup>

**DISCUSSION**

Monro, who removed a loose body from the ankle produced by traumatic injury, most likely provided the first description of an ankle OCL. Monro was the first person to describe an ankle OCL. Since then, numerous etiologies have been described that may contribute to the formation of these lesions. These etiologies include acute trauma, chronic

microtrauma, endocrine or metabolic factors, genetic predisposition, joint displacement, osteoarthritis, and avascular necrosis. Chronic microtrauma occurs over time. Nonetheless, trauma is still the most common reason that causes OCLs. Flick and Gould came to the conclusion that out of 500 individuals with OCLs, 90% of lateral dome lesions and 70% of medial dome lesions could be ascribed to a traumatic incident.<sup>11</sup> Due to the absence of blood vessels, articular hyaline cartilage has a limited potential for the body to repair itself. In addition, when an osteochondral lesion does not extend beyond the subchondral plate, the body does not produce an inflammatory response in order to drive regeneration. This is because an osteochondral lesion cannot affect the cartilage that is beneath the subchondral plate. In the case of lesions that affect the subchondral bone, an inflammatory response will drive the formation of repair tissue by marrow cells in an effort to fill the void left by the lesion.<sup>11</sup>

This is done in an attempt to fill the gap caused by the lesion. This fundamental concept serves as the foundation for a variety of techniques for stimulating bone marrow, such as microdrilling and microfracturing.<sup>11</sup> The management of osteochondral lesions of the talus can be accomplished through the use of a variety of therapeutic techniques. Options include conservative care, which can take the form of immobilization or protective weight bearing, and surgical treatment, which can consist of either reparative or replacement therapies. Both of these treatments are discussed further below.<sup>13</sup>

The most important thing that was discovered as a result of this investigation was that there was a lack of information in the published literature concerning the use of BMAC for the treatment of OLTs with very different indications, associated procedures, and outcome evaluations. This was the most important thing that was discovered as a result of this investigation. The significance of this finding could not be overstated. This was the most significant discovery that was made as a result of the investigation.<sup>13</sup>

On the other hand, the clinical trials that were looked at suggested a variety of excellent outcomes for the treatment of moderately sized chondral lesions, and none of the studies found any serious problems that needed to be addressed. Only one of the studies that were considered for inclusion in this analysis was a prospective study, and it was the only one that contained a control group. This is despite the fact that all three of the studies that were analyzed for this analysis had quality that ranged from moderate to high, according to the mCMS's assessment of the studies' characteristics.<sup>13</sup>

It is common practice to harvest mesenchymal stem cells, other progenitor cells, and the associated cytokines and growth factors from bone marrow that has been obtained by aspiration from the iliac crest. It is one of the few ways to acquire progenitor cells and growth factors for subsequent injection, and the use of bone marrow aspirate concentrate (BMAC), which is currently approved for use by the Food and Drug Administration of the United States, is one of the reasons for this approval.<sup>18</sup>

The bone marrow aspirate (BMA) sample must be processed after it is harvested. BMA is filtered through a 200- $\mu$ m-mesh filter into 50-mL conical tubes. Then, 1 to 1.5 mL of the filtered BMA is pipetted into a 2-mL microcentrifuge tube for hemanalysis and the sample complete blood count with differential is automatically recorded. Subsequently, 60 to 90 mL of BMA is transferred into 2  $\times$  50-mL conical tubes, and initially centrifuged at 2,400 rpm for 10 minutes.<sup>18</sup>

After completion of this process, the buffy coat layer and platelet-poor plasma layer are extracted from the conical tube and discarded. The red blood cell layers are combined into 1  $\times$  50-mL conical tube for second centrifugation (3,400 rpm for 6 minutes). Finally, the BMAC/white cell pellet is resuspended in platelet poor plasma, hemanalysis is performed and complete blood count with differential is recorded (including monocyte count) to assess the final product to inject.<sup>18</sup>

With time, the AOFAS score exhibited a small decline. Despite being statistically significant, this drop falls short of the minimum clinically relevant difference (MCID), which was defined at 8.9 in prior research.<sup>9,14</sup> The MCID threshold is increasingly utilized to determine the clinical significance of reported score changes. In this light, patient-perceived outcomes were rather steady and still significantly superior than pre-operative levels. Moreover, particularly in terms of the AOS score, both pain and disability parameters shown a significant improvement up to 10 years.<sup>5,19</sup>

This is a significant feature because the AOS score is a disease-specific measure with high overall reliability for ankle OA. Good results overall indicate the need to further develop and research regeneration alternatives, even in such problematic young patients with OLT-affected OA joints. This series enabled us to discover a number of prognostic markers for patients receiving this salvage operation, including some contentious findings in comparison to previous research. Herrera-Perez et al. shown in 2019 that surgical ankle debridement for post-traumatic osteochondral lesions resulted in a much greater revision and failure rate than patients treated with concomitant treatments.<sup>20</sup>

In contrast, those who required combination treatments performed poorly in this study. This could be due to distinct etiopathological reasons as well as the more complex abnormalities of joints that required additional surgical procedures. In this particular study, having both procedures performed at the same time had a negative impact on the outcome. In point of fact, patients who had combination surgery had a lower likelihood of being willing to undertake the treatment again, and patients who had previous fractures had a lower likelihood of having a successful outcome. If the joint or the alignment of the ankle and foot is typically altered, treatment may be necessary.<sup>5,19</sup>

There were very few reports of complications, and none of those reported difficulties were determined to be caused by the BMAC injection itself. There were very few complaints of complications. Only a superficial infection at a portal site was identified during the experiment that utilized scaffold-assisted BMAC. Three of the patients who had received BMAC-soaked OAT reported experiencing pain associated with donor site morbidity, and an MRI that was done at a follow-up period of 28 months revealed that one of the patients had developed a cyst beneath the graft site.<sup>5,7</sup>

Two patients reported experiencing superficial peroneal nerve dysesthesia after undergoing treatment with microfracture and BMAC. No instances of neoplasia or abnormally high amounts of bone formation were found in the patients who were evaluated. When Giannini et al. (2009) performed a second-look arthroscopy on two symptomatic patients, they found evidence of chondral hypertrophy in each of those individuals. It would appear that using bone marrow aspirate as a biologic supplement is a risk-free activity in and of itself.<sup>13,21</sup>

## CONCLUSION

According to the findings of this analysis, there is an alarming dearth of long-term data and high-level evidence to support the utilization of this therapeutic strategy. In spite of this, the evidence that was available demonstrated that BMAC was advantageous for the treatment of ankle cartilage abnormalities, albeit to different degrees of effectiveness.

## REFERENCE

- [1] Leumann A, Valderrabano V, Plaass C, Rasch H, Studler U, Hintermann B, et al. A Novel Imaging Method for Osteochondral Lesions of the Talus—Comparison of SPECT-CT With MRI. *Am J Sports Med* [Internet]. 2011 Feb 7;39(5):1095–101. Available from: <https://doi.org/10.1177/0363546510392709>
- [2] Potter HG, Chong LR, Sneag DB. Magnetic Resonance Imaging of Cartilage Repair. *Sports Med Arthrosc* [Internet]. 2008;16(4). Available from: [https://journals.lww.com/sportsmedarthro/Fulltext/2008/12000/Magnetic\\_Resonance\\_Imaging\\_of\\_Cartilage\\_Repair.8.aspx](https://journals.lww.com/sportsmedarthro/Fulltext/2008/12000/Magnetic_Resonance_Imaging_of_Cartilage_Repair.8.aspx)
- [3] Saw K-Y, Hussin P, Loke S-C, Azam M, Chen H-C, Tay Y-G, et al. Articular cartilage regeneration with autologous marrow aspirate and hyaluronic acid: an experimental study in a goat model. *Arthrosc J Arthrosc Relat Surg*. 2009;25(12):1391–400.
- [4] Kraeutler MJ, Chahla J, LaPrade RF, Pascual-Garrido C. Biologic options for articular cartilage wear (platelet-rich plasma, stem cells, bone marrow aspirate concentrate). *Clin Sports Med*. 2017;36(3):457–68.
- [5] Savage-Elliott I, Ross KA, Smyth NA, Murawski CD, Kennedy JG. Osteochondral lesions of the talus: a current concepts review and evidence-based treatment paradigm. *Foot Ankle Spec*. 2014 Oct;7(5):414–22.
- [6] Sampson S, Botto-van Bemden A, Aufiero D. Autologous bone marrow concentrate: review and application of a novel intra-articular orthobiologic for cartilage disease. *Phys Sportsmed*. 2013 Sep;41(3):7–18.
- [7] Kennedy JG, Murawski CD. The Treatment of Osteochondral Lesions of the Talus with Autologous Osteochondral Transplantation and Bone Marrow Aspirate Concentrate: Surgical Technique. *Cartilage*. 2011 Oct;2(4):327–36.
- [8] Giannini S, Buda R, Battaglia M, Cavallo M, Ruffilli A, Ramponi L, et al. Onestep repair in talar osteochondral lesions: 4-year clinical results and t2-mapping capability in outcome prediction. *Am J Sports Med*. 2013;41(3):511–8.
- [9] Vannini F. One-Step Repair in Talar Osteochondral Lesions. *Am J Sports Med*. 2013;41(3).
- [10] Fortier LA, Potter HG, Rickey EJ, Schnabel L V, Foo LF, Chong LR, et al. Concentrated bone marrow aspirate improves full-thickness cartilage repair compared with microfracture in the equine model. *JBJS*. 2010;92(10):1927–37.
- [11] Smyth NA, Murawski CD, Haleem AM, Hannon CP, Savage-Elliott I, Kennedy JG. Establishing proof of concept: platelet-rich plasma and bone marrow aspirate concentrate may improve cartilage repair following surgical treatment for osteochondral lesions of the talus. *World J Orthop*. 2012;3(7):101.
- [12] Betsch M, Schnependahl J, Thuns S, Herten M, Sager M, Jungbluth P, et al. Bone marrow aspiration concentrate and platelet rich plasma for osteochondral repair in a porcine osteochondral defect model. *PLoS One*. 2013;8(8):e71602.
- [13] Hannon CP, Ross KA, Murawski CD, Deyer TW, Smyth NA, Hogan M V, et al. Arthroscopic bone marrow stimulation and concentrated bone marrow aspirate for osteochondral lesions of the talus: a case-control study of functional and magnetic resonance observation of cartilage repair tissue outcomes. *Arthrosc J Arthrosc Relat Surg*. 2016;32(2):339–47.
- [14] Vannini F, Filardo G, Altamura SA, Di Quattro E, Ramponi L, Buda R, et al. Bone marrow aspirate concentrate and scaffold for osteochondral lesions of the talus in ankle osteoarthritis: satisfactory clinical outcome at 10 years. *Knee Surg Sports Traumatol Arthrosc*. 2021 Aug;29(8):2504–10.
- [15] Kim BS, Na Y, Jang D-S. Outcomes of bone marrow aspirate concentrate and matrix-induced chondrogenesis (BMIC) for treatment of osteochondral lesions of the talus. *Foot ankle Surg Off J Eur Soc Foot Ankle Surg*. 2022 Oct;28(7):944–9.
- [16] Murphy EP, McGoldrick NP, Curtin M, Kearns SR. A prospective evaluation of bone marrow aspirate concentrate and microfracture in the treatment of osteochondral lesions of the talus. *Foot Ankle Surg*. 2019 Aug;25(4):441–8.
- [17] Dávila Castrodad IM, Simone ES, Kurowicki J, Melendez JX, Mease SJ, McInerney VK, et al. Improved Short-Term Outcomes of Osteochondral Lesions of the Knee Following Arthroscopic Treatment With Bone Marrow Aspirate Concentrate and Cartilage-Derived Matrix. *Arthrosc Sport Med Rehabil*. 2021 Apr;3(2):e477–84.

- [18] Chahla J, Mannava S, Cinque ME, Geeslin AG, Codina D, LaPrade RF. Bone Marrow Aspirate Concentrate Harvesting and Processing Technique. *Arthrosc Tech.* 2017 Apr;6(2):e441–5.
- [19] Ishijima M, Nakamura T, Shimizu K, Hayashi K, Kikuchi H, Soen S, et al. Intraarticular hyaluronic acid injection versus oral non-steroidal anti-inflammatory drug for the treatment of knee osteoarthritis: a multi-center, randomized, open-label, non-inferiority trial. *Arthritis Res Ther.* 2014;16(1):1–8.
- [20] Herrera-Perez M, Alrashidi Y, Galhoum AE, Kahn TL, Valderrabano V, Barg A. Debridement and hinged motion distraction is superior to debridement alone in patients with ankle osteoarthritis: a prospective randomized controlled trial. *Knee Surgery, Sport Traumatol Arthrosc.* 2019;27:2802–12.
- [21] Giannini S, Buda R, Vannini F, Cavallo M, Grigolo B. One-step bone marrowderived cell transplantation in talar osteochondral lesions. *Clin Orthop Relat Res.* 2009 Dec;467(12):3307–20.