

THE SYSTEMATIC REVIEW OF RADIOLOGIC IMAGING IN SUSPECTED RENAL COLIC

^{1*}Yoga Nuswantoro, ¹Efa Anggraini

¹Faculty of Medicine, University of Muhammadiyah, Surakarta, Indonesia

Corresponding Author:

yoga.nuswantoro@gmail.com

ABSTRACT

Background: Renal colic, a common cause of morbidity, is characterized by acute, intermittent flank pain. Diagnosis involves a combination of history, physical exam, laboratory testing, and imaging studies. In recent years, the assessment of individuals suspected of having renal colic has become increasingly dependent on imaging. Renal ultrasound is not reliable for seeing ureteral calculi and may miss smaller stones. Besides, the use of CT increased radiation exposure and high medical costs.

The aim: This study aims to determine the radiologic imaging in patients with suspected renal colic. **Methods:** By comparing itself to the standards set by the Preferred Reporting Items for Systematic Review and Meta-Analysis (PRISMA) 2020, this study was able to show that it met all of the requirements. So, the experts were able to make sure that the study was as up-to-date as it was possible to be. For this search approach, publications that came out between 2014 and 2024 were taken into account. Several different online reference sources, like PubMed and ScienceDirect, were used to do this. It was decided not to take into account review pieces, works that had already been published, or works that were only half done.

Results: In the PubMed database, the results of our search brought up 162 articles, whereas the results of our search on ScienceDirect brought up 135 articles. The results of the search conducted by title screening yielded a total 25 articles for PubMed and 15 articles for ScienceDirect. We compiled a total of 21 papers, 17 of which came from PubMed and 4 of which came from ScienceDirect. We excluded 2 review articles, 4 duplicate articles, 1 non-full text article, 1 article having ineligible subject and 4 articles having insufficient outcomes data. In the end, we included nine research that met the criteria.

Conclusion: The use of point-of-care ultrasound (POCUS) in patients with suspected renal colic may avoid the use of CT. Although, the accuracy is lower than CT, but it can reduce medical expense and induced radiation exposure.

Keywords: Ureterolithiasis, renal colic, diagnostic imaging, acute setting

INTRODUCTION

Acute and severe loin discomfort brought on by renal stones impeding urine flow is referred to renal colic. The classical presentation of renal colic is acute, intermittent flank pain radiating to the groin or scrotum.¹ Acute blockage of the ureters, pedicle traction, or compression or stretching of the renal pelvis or peripelvic capsule can all result in renal colic. Severity of renal colic is associated with acuity rather than degree of obstruction. Renal colic normally lasts 3–18 hours and progresses in regular phases, peaking in 30-120 minutes.²

Renal colic, which affects three out of every 1000 individuals annually, is a common cause of morbidity.¹ Renal colic occurred 1% to 15% during a lifetime; however, this varies based on age, sex, race, and geographical location.³ An estimated 6% of women and 12% of men may experience one episode of renal colic in their lifetime.¹ Diagnosis is made through a combination of history and physical exam, laboratory testing, and imaging studies.

Nowadays, the assessment of individuals suspected of having renal colic has become more and more dependent on imaging. In the USA, the percentage of ED visits for suspected urolithiasis when patients had imaging climbed from 56% in 1995-1997 to 79% in 2007-2009.⁴ The current European Association of Urology guidelines state that in patients with suspected urolithiasis, ultrasound should be the primary diagnostic imaging examination.⁵ Renal ultrasound is not a reliable imaging technique for seeing ureteral calculi, and it frequently misses stones smaller than 5 mm in size. However, it can be used to follow larger renal stones (particularly uric acid) and establish hydronephrosis.⁶ The use of CT in younger patients has increased from 19% of visits in 1998-2000 to 73% of visits in 2007-2009. Radiation exposure and relatively high medical costs have been brought on by this growing use of imaging, especially MDCT.⁴ This study aims to determine the radiologic imaging in patients with suspected renal colic.

METHODS

Protocol

By following the rules provided by Preferred Reporting Items for Systematic Review and Meta-Analysis (PRISMA) 2020, the author of this study made certain that it was up to par with the requirements. This is done to ensure that the conclusions drawn from the inquiry are accurate.

Criteria for Eligibility

For the purpose of this systematic review, we compare and contrast radiologic imaging in suspected renal colic. It is possible to accomplish this by researching or investigating the diagnostic accuracy and outcomes of ultrasound and CT scan in suspected renal colic. As the primary purpose of this piece of writing, demonstrating the relevance of the difficulties that have been identified will take place throughout its entirety.

In order for researchers to take part in the study, it was necessary for them to fulfil the following requirements: 1) The paper needs to be written in English, and it should focus on determining diagnostic imaging in suspected renal colic. In order for the manuscript to be considered for publication, it needs to meet both of these requirements. 2) The studied papers include several that were published within the last 10 years. Examples of studies that are not permitted include editorials, submissions that do not have a DOI, review articles that have already been published, and entries that are essentially identical to journal papers that have already been published.

Search Strategy

We used "renal colic"; "diagnostic imaging"; and "emergency" as keywords. The search for studies to be included in the systematic review was carried out from January, 7th 2024 using the PubMed and ScienceDirect databases by inputting the words: "renal colic"[MeSH Terms] OR "renal"[All Fields] AND "colic"[All Fields] OR "renal colic"[All Fields] AND "diagnostic imaging"[MeSH Subheading] OR "diagnostic"[All Fields] AND "imaging"[All Fields] OR "diagnostic imaging"[All Fields] OR "diagnostic imaging"[MeSH Terms] AND "emerge"[All Fields] OR "emerged"[All Fields] OR "emergence"[All Fields] OR "emergences"[All Fields] OR "emergencies"[MeSH Terms] OR "emergencies"[All Fields] OR "emergency"[All Fields] OR "emergent"[All Fields] OR "emergently"[All Fields] OR "emergents"[All Fields] OR "emerges"[All Fields] OR "emerging"[All Fields] AND (y_10[Filter]) AND (english[Filter]) used in searching the literature.

Data retrieval

After reading the abstract and the title of each study, the writers performed an examination to determine whether or not the study satisfied the inclusion criteria. The writers then decided which previous research they wanted to utilise as sources for their article and selected those studies. After looking at a number of different research, which all seemed to point to the same trend, this conclusion was drawn. All submissions need to be written in English and can't have been seen anywhere else.

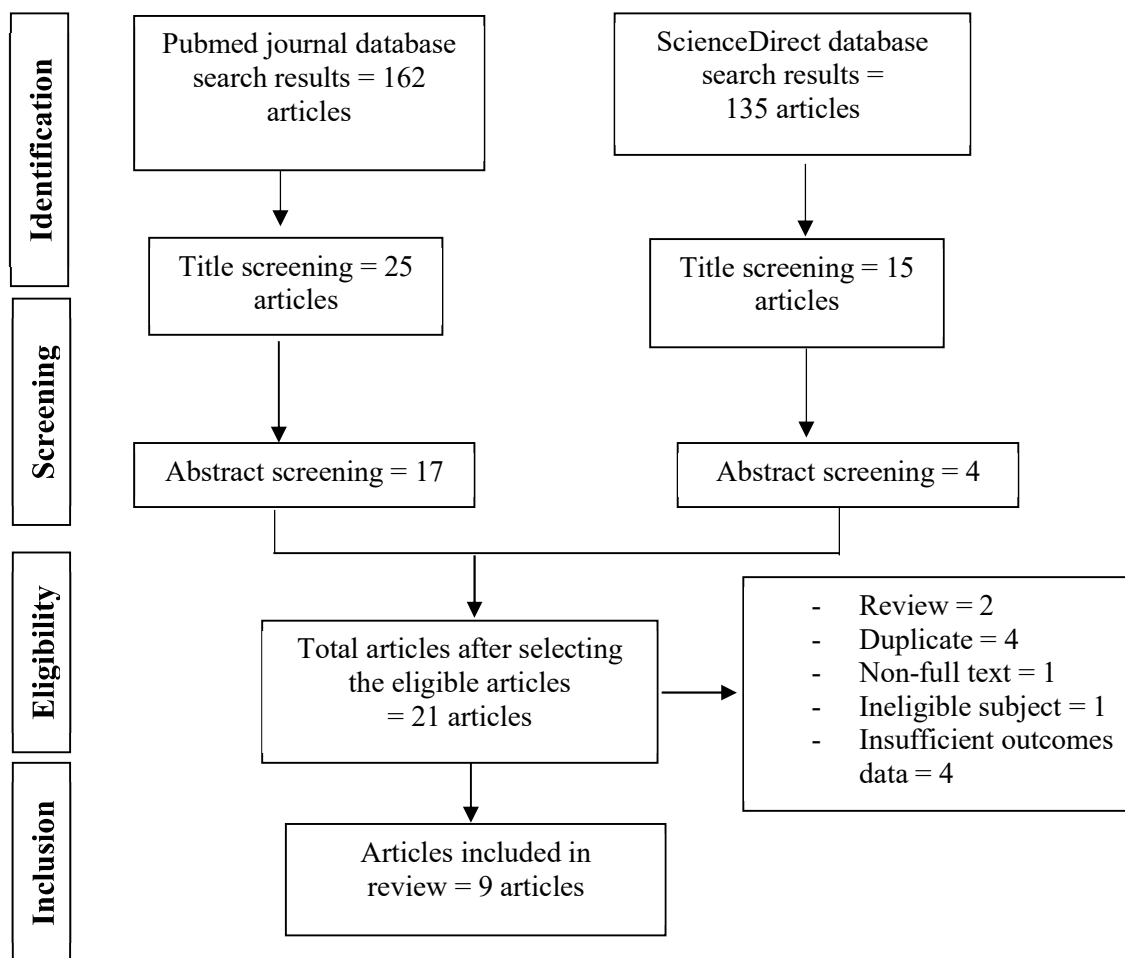


Figure 1. Article search flowchart

Only those papers that were able to satisfy all of the inclusion criteria were taken into consideration for the systematic review. This reduces the number of results to only those that are pertinent to the search. We do not take into consideration the conclusions of any study that does not satisfy our requirements. After this, the findings of the research will be analysed in great detail. The following pieces of information were uncovered as a result of the inquiry that was carried out for the purpose of this study: names, authors, publication dates, location, study activities, and parameters.

Quality Assessment and Data Synthesis

Each author did their own study on the research that was included in the publication's title and abstract before making a decision about which publications to explore further. The next step will be to evaluate all of the articles that are suitable for inclusion in the review because they match the criteria set forth for that purpose in the review. After that, we'll determine which articles to include in the review depending on the findings that we've uncovered. This criteria is utilised in the process of selecting papers for further assessment in order to simplify the process as much as feasible when selecting papers to evaluate. Which earlier investigations were carried out, and what elements of those studies made it appropriate to include them in the review, are being discussed here.

RESULT

In the PubMed database, the results of our search brought up 162 articles, whereas the results of our search on ScienceDirect brought up 135 articles. The results of the search conducted by title screening yielded a total 25 articles for PubMed and 15 articles for ScienceDirect. We compiled a total of 21 papers, 17 of which came from PubMed and 4 of which came from ScienceDirect. We excluded 2 review articles, 4 duplicate articles, 1 non-full text article, 1 article having ineligible subject and 4 articles having insufficient outcomes data. In the end, we included nine research that met the criteria.

Table 1. The literature include in this study

Author	Origin	Method	Sample Size	Result
Al-Balushi, 2022 ⁷	Oman	Cross-sectional	303 participants	This findings concluded that bedside renal point-of-care ultrasound (POCUS) performed in patients with suspected renal colic has a moderate sensitivity to detect hydronephrosis and grade its severity. Therefore, it should be utilised in the ED to screen patients for hydronephrosis.
Blecher, 2017 ⁸	Australia	Quasi-experimental prospective study	324 participants	The results showed that the use of CT urography (CTU) for renal colic was significantly reduced by introduction of a guideline promoting ultrasound and encouraging selective CTU, with ED PoCUS as the initial imaging and CTU reserved for those with 'red flags' or poor analgesic response.
Bourcier, 2021 ⁹	France	Prospective observational study	103 participants	This findings suggested that point-of-care ultrasound (PoCUS) is a good diagnostic tool for renal colic. PoCUS could help reduce the requirement for the CT examinations and, hence, reduce induced radiation exposure.

Kepka, 2023 ¹⁰	France	Retrospective study	273 participants	This result shows that CT diagnostic workup for renal colic reduced the length of stay and cost compared to ultrasound. However, the main limitation of CT remains radiation exposure, especially in young patients or pregnant women. Thus, it is essential to limit the use of imaging to patients for whom it is strictly necessary.
Kim, 2019 ¹¹	Korea	RCT	218 participants	This result suggested that applying POCUS-US protocol as initial diagnostic for patients with acute renal colic in the ED can reduce the ED length of stay and medical cost without 30-day complication than usual clinical practice.
Ng, 2015 ¹²	USA	Case series	5 participants	This findings reported five cases of renal colic patients where urolithiasis was confirmed by using POCUS and irradiation by CT was avoided in all 5 patients.
Roberts, 2020 ¹³	Australia	Prospective cohort study	21 participants	This result showed that ultra-low-dose computed tomography (ULDCT) was comparable to standard-dose CT (SDCT) for calculus detection and size estimation with reduced radiation exposure. ULDCT should be considered as the first-line modality for evaluation of renal colic in routine practice.

Shrestha, 2017 ¹⁴	Nepal	Retrospective study	201 participants	This findings concluded that US should be used in all cases suspected ureteric colic. The most significant finding is hydronephrosis. The absence of hydronephrosis probably suggests small or passed out calculus requiring no urological intervention or may indicate alternate diagnosis.
Sibley, 2020 ¹⁵	Canada	Prospective observational study	413 participants	This findings suggested PoCUS for hydronephrosis has moderate sensitivity and specificity for renal colic limiting its utility as a diagnostic test. However, PoCUS is inexpensive and readily available test, it may be useful to help guide further imaging and consultation in conjunction with clinical course.

Ultrasound

Al-Balushi, et al. (2022)⁷ showed that ureteral stones with hydronephrosis detected on renal POCUS exhibited 75.8% sensitivity and 55.2% specificity, with a positive likelihood ratio of 1.69 (95% CI: 1.32–2.16) and a negative likelihood ratio of 0.43 (95% CI: 0.32–0.59).

Blecher, et al. (2017)⁸ showed that twenty-four of the 49 patients (49.0%) who had ultrasound eventually went on to have a CTU, whereas 40 of the 76 patients (52.6%) with no ultrasound ended up with a CTU. The most common reasons for non-performance of ultrasound were: no accredited doctor present (32/73, 43.8%) and accredited doctor present but no time to perform the test (21/73, 28.8%).

Bourcier, et al. (2021)⁹ showed that the performance of PoCUS in detecting lithiasis, and therefore ureteral colic was as follow: accuracy, 54%; sensitivity, 43%; and specificity, 92%. Among the 85 patients diagnosed with ureteral colic, 43 had lithiasis not detected on ultrasound (14 in the bladder–ureteral junction, six in the pelvic ureter, 21 in the lumbar ureter, and two in the proximal ureter).

Kim, et al. (2019)¹¹ showed that the ED length of stay was significantly lower in the POCUS-US group. The subgroup diagnosed as ureter stone in the UG group showed meaningful distinction in terms of length of stay compared with the CG group, 74 min (UG 157 min (95% CI 144–171 min) vs. CG 231 min (211–251 min), p-value for difference <0.001). Medical cost was significantly lower in the UG than in the CG. The difference in the subgroup of diagnosed with ureter stone was 63 USD (UG 247 (95% CI 233-260) USD vs. CG 310 (95% CI 298-322) USD; p < 0.001). Nevertheless, the time from performing CT scan to ED discharge was not significantly different between the CG and UG.

Ng, et al. (2015)¹² showed that in each of five patients with renal colic, urolithiasis was confirmed by using POCUS, and CT was avoided. The POCUS diagnosis of urolithiasis allowed for more efficient management of the patient’s renal colic without obtaining a CT. In case 1, the POCUS examination showed a 6.6-mm stone identified in the right ureterovesical junction with twinkling artifact and right hydronephrosis. In case 2, POCUS examination revealed right hydroureteronephrosis with diminished right ureteral jet compared to the left side. In case 3, POCUS examination identified the migration of a left ureteral stent into the bladder with hydronephrosis of the left kidney and intrarenal stones with twinkling artifact. In case 4, POCUS showed a 10-mm stone in the right ureterovesical junction in a 3-year-old boy with persistent dysuria, despite antibiotic treatment for a urinary tract infection. In case 5, POCUS showed the decreased ureteral jet on the left was consistent with partial obstruction of the left ureter.

Shrestha, et al. (2017)¹⁴ showed that US was performed amongst 67% (134/201) of the total patient out of which ureteric stones were detected in 45.5% (61/134) of cases, 32.8% (44/134) were reported to be normal, and other abnormalities were reported in 21.6% (29/134) cases. All cases of ureteric colic with location of stone at proximal ureter (9/9) and 87.8% (36/41) at distal ureter had hydronephrosis ($p=0.05$). Sensitivity, specificity, positive predictive value and negative predictive value for hydronephrosis in relation to stones in US in this study was 85.2%, 94.5%, 92.9% and 88.5%, respectively.

Sibley, et al. (2020)¹⁵ showed the sensitivity of POCUS for the detection of hydronephrosis was 77.1% [95% CI 70.9, 82.6] and the specificity was 71.8% [95% CI 65.0, 77.9]. The sensitivity of PoCUS improved with worsening degrees of hydronephrosis. These measures did not improve appreciably for patients with confirmed stone or signs of recent stone passage on formal imaging (sensitivity 78.2 [95% CI 71.3, 84.1], specificity 74.2 [95% CI 55.4, 88.1]), or when considering only patients who had a CT scan (sensitivity 75.9 [95% CI 69.2, 81.8], specificity 72.3 [95% CI 64.7, 79.1]).

Computed Tomography (CT)

Al-Balushi, et al. (2022)⁷ showed that around two-thirds of patients who presented to the emergency department (ED) with the signs and symptoms of renal colic had hydronephrosis on non-contrast computed tomography (NCCT). Ureteral stones were present in 207 (68.3%) NCCT reports, with hydronephrosis was present in 216 (71.3%) NCCT scans. Nevertheless, hydronephrosis without ureteral stones was noted in nine (3.0%) NCCT scans.

Blecher, et al. (2017)⁸ showed that CT urography (CTU) was performed at the initial visit for 80/148 (54.1%, 95% CI 45.7 to 62.3) at Monash and 132/176 (75.0%, 95% CI 67.9 to 81.2) at Dandenong, $p<0.001$. Of the 125, 115 (92.0%) had clinical outcome information recorded. CTU rates from highest to lowest: no ultrasound and poor clinical response (6/6, 100%), ultrasound done and poor clinical response (7/9, 77.8%), no ultrasound and good response (30/63, 47.6%) and ultrasound done with good response (14/37, 37.8%).

Bourcier, et al. (2021)⁹ showed that eight patients diagnosed with renal colic had no ureteral lithiasis on CT, but had pyelocalyceal cavity dilatation. Six of them had bladder lithiasis and two had spontaneous elimination of stones between the PoCUS and CT examinations.

Kepka, et al. (2023)¹⁰ showed that 273 patients diagnosed with renal colic, the performance of CT as initial imaging for patients presenting in the ED with suspected ureteral stone reduced ED LOS by a mean of 0.139 [CI 95% -1.1; 1.5] hours and was cost-saving, with a reduction of € - 199 [CI 95% -745; 285] per patient and a 50% probability of dominance in favour of CT over US. The average 60-day unadjusted costs in euros were estimated to be €1159 (± 1987) and €956 (± 1462) for the "US group" and "CT group," respectively.

Roberts, et al. (2020)¹³ showed that patients who underwent standard-dose CT (SDCT) had more calculi ($n = 17$) detected than those undergoing ultra-low-dose computed tomography (ULDCT) ($n = 13$). A total of 12 patients (57.1%) had renal or ureteric calculi detected. Renal calculi ($n = 9$) were detected in eight patients according to SDCT. Three of the eight patients showed concordant calculus detection without significant differences detected in size between SDCT and ULDCT. Patients who underwent SDCT had more calculi ($n = 17$) detected than those undergoing ULDCT ($n = 13$). Calculus sizes were similar according to position and imaging modality ($P > 0.05$), while most ureteric calculi were distal (six of eight SDCT and four of six ULDCT) without being significantly different in size ($P > 0.05$).

DISCUSSION

The purpose of this research was to review studies published after January of 2014 and up to January of 2024 that investigated the diagnostic accuracy and outcomes of ultrasound and CT scan in suspected renal colic. The most common differential diagnosis for renal colic is renal and ureteral stone disease. However, similar symptoms and indications can also be observed in other diseases of the urinary system, including pancreatic, gastrointestinal, gynecological, hepatobiliary, vascular, and musculoskeletal disorders; pyelonephritis also falls under this category. Imaging methods and lab testing are used to achieve an accurate differential diagnosis. Renal colic is most commonly diagnosed by KUB, USG, and CT imaging modalities.

In this review, all identified studies suggested ultrasound (POCUS) had lower sensitivity and specificity for renal colic than CT. The range varied widely. CT has become the imaging study of choice for renal colic because of its high sensitivity in the detection of renal and ureteral stones. Furthermore, dual energy CT imaging aids in characterizing the composition of renal stones. The majority of hospitals, however, lack this equipment, which is also of very limited utility in the event of ureteral stones. With a very high accuracy of $>95\%$, CT can identify the existence and size of stones. In 5–10% of patients, it can also reveal other conditions that mimic renal colic. Although the use of CT scans seldom alters the treatment plans of these patients, there is growing worry about the rise in health care expenses and radiation risk associated with them, despite the scans' excellent accuracy.¹⁶ However, a study by Smith-Bindman et al. revealed no statistically significant differences in high-risk diagnoses, complications, serious adverse events, self-reported pain scores, return ED visits, or hospitalizations among patients who had been evaluated by US at initial presentation in contrast to MDCT.¹⁷

A study suggested CT was still used for further examination in 40% of patients who had POCUS and 27% of patients who had conventional renal US. Merely 5% of patients who underwent initial CT scan also underwent US imaging. The mean total cost of the ED visit was, nevertheless, somewhat cheaper for patients who had US before, even with the additional imaging.⁴ This review suggested the use of US as initial imaging can avoid the use CT. In addition, ED length of stay was significantly lower, thus lowering the costs. There was strong agreement to avoid further imaging regardless of the POCUS outcome and a consensus for POCUS to be the first imaging modality. POCUS may not be necessary if the next course of action is to perform no more imaging, regardless of the outcome of the POCUS (hydronephrosis or not).

CONCLUSION

The use of point-of-care ultrasound (POCUS) in patients with suspected renal colic may avoid the use of CT. Although, the accuracy is lower than CT, but it can reduce medical expense and induced radiation exposure.

REFERENCES

- [1] Gandhi A, Hashemzoh T, Batura D. The management of acute renal colic. 2019.
- [2] Thia I, Saluja M. An update on management of renal colic. Vol. 11, *International Journal of Emergency Medicine*. Springer London; 2021.
- [3] Torabi M, Shojaee F, Mirzaee M. Prevalence of Renal Colic in the Emergency Departments: A Multi-center Study. *Hosp Pract Res*. 2021 Aug 1;6(3):123–6.
- [4] Alabousi A, Patlas MN, Mellnick VM, Chernyak V, Farshait N, Katz DS. Renal Colic Imaging: Myths, Recent Trends, and Controversies. Vol. 70, *Canadian Association of Radiologists Journal*. Canadian Medical Association; 2019. p. 164–71.
- [5] Türk C, Petřík A, Sarica K, Seitz C, Skolarikos A, Straub M, et al. EAU Guidelines on Diagnosis and Conservative Management of Urolithiasis. *Eur Urol*. 2016 Mar 1;69(3):468–74.
- [6] Patti L, Leslie SW. Acute Renal Colic [Internet]. 2022. Available from: <https://www.ncbi.nlm.nih.gov/books/NBK431091/>
- [7] Al-Balushi A, Al-Shibli A, Al-Reesi A, Ullah QZ, Al-Shukaili W, Baawain S, et al. The Accuracy of Point-of-Care Ultrasound Performed by Emergency Physicians in Detecting Hydronephrosis in Patients with Renal Colic. *Sultan Qaboos Univ Med J*. 2022 Aug 1;22(3):351–6.
- [8] Blecher G, Meek R, Egerton-Warburton Di, McCahy P. Introduction of a new imaging guideline for suspected renal colic in the ED reduces CT urography utilisation. *Emergency Medicine Journal*. 2017 Nov 1;34(11):749–54.
- [9] Bourcier JE, Gallard E, Redonnet JP, Abillard M, Billaut Q, Fauque L, et al. Ultrasound at the patient’s bedside for the diagnosis and prognostication of a renal colic. *Ultrasound Journal*. 2021 Dec 1;13(1).
- [10] Kepka S, Zarca K, Ohana M, Hoffmann A, Muller J, Le Borgne P, et al. A Real-World Cost-Effectiveness Study Evaluating Imaging Strategies for the Diagnostic Workup of Renal Colic in the Emergency Department. *Medicina (Lithuania)*. 2023 Mar 1;59(3).
- [11] Kim SG, Jo IJ, Kim T, Hwang SY, Park JH, Shin TG, et al. Usefulness of protocolized point-of-care ultrasonography for patients with acute renal colic who visited emergency department: A randomized controlled study. *Medicina (Lithuania)*. 2019 Nov 1;55(11).
- [12] Ng C, Tsung JW. Avoiding computed tomography scans by using point-of-care ultrasound when evaluating suspected pediatric renal colic. *Journal of Emergency Medicine*. 2015 Aug 1;49(2):165–71.
- [13] Roberts MJ, Williams J, Khadra S, Nalavenkata S, Kam J, McCombie SP, et al. A prospective, matched comparison of ultra-low and standard-dose computed tomography for assessment of renal colic. *BJU Int*. 2020 Sep 1;126(S1):27–32.
- [14] Shrestha R, Bista Y, Khan A. Current Diagnostic Approach and Initial Treatment Patterns for Renal Colic in Emergency Department. Vol. 15, *JNHRC*. 2017.
- [15] Sibley S, Roth N, Scott C, Rang L, White H, Sivilotti MLA, et al. Point-of-care ultrasound for the detection of hydronephrosis in emergency department patients with suspected renal colic. *Ultrasound Journal*. 2020 Dec 1;12(1).
- [16] Nicolau C, Claudon M, Derchi LE, Adam EJ, Nielsen MB, Mostbeck G, et al. Imaging patients with renal colic—consider ultrasound first. Vol. 6, *Insights into Imaging*. Springer Verlag; 2015. p. 441–7.
- [17] Smith-Bindman R, Aubin C, Bailitz J, Bengiamin RN, Camargo CA, Corbo J, et al. Ultrasonography versus Computed Tomography for Suspected Nephrolithiasis. *New England Journal of Medicine*. 2014 Sep 18;371(12):1100–10.